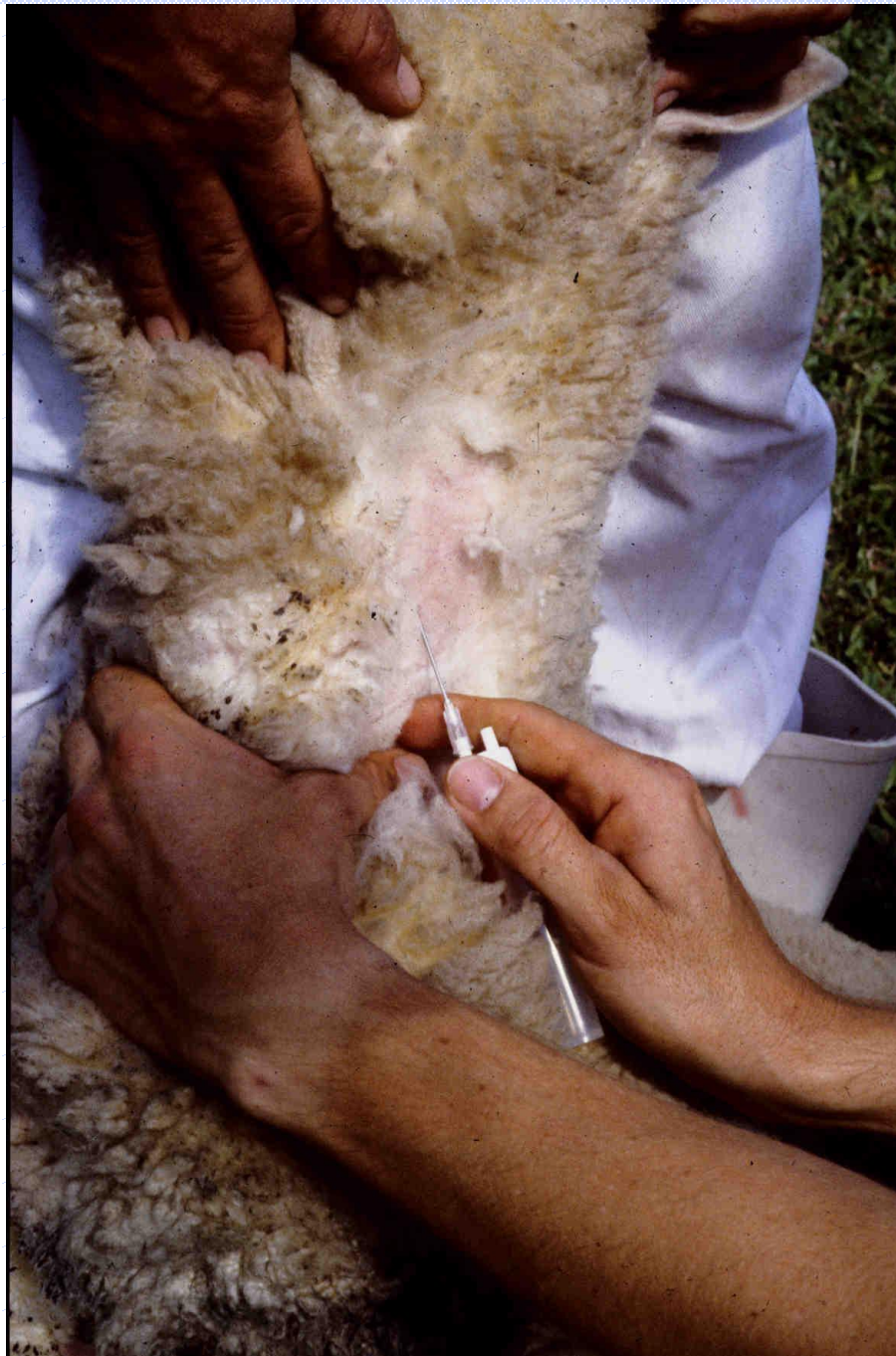



Male Reproductive Disease

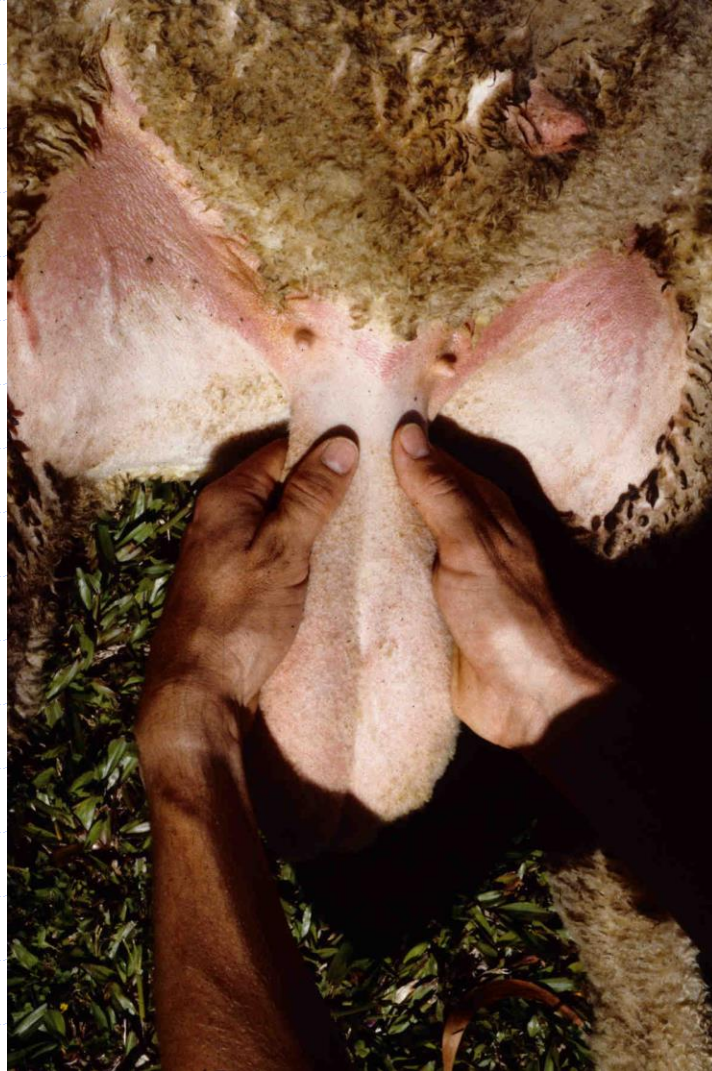Functional Anatomy

Gross Pathology

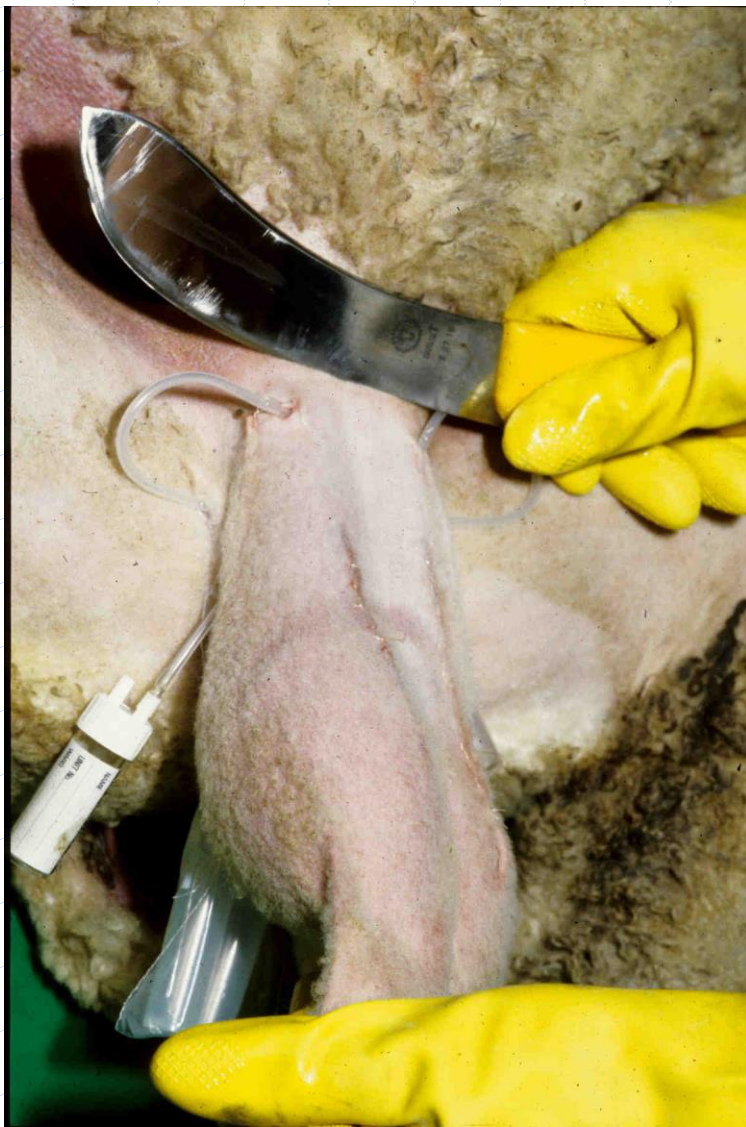
PM: Serology



PM: Palpate spermatic cord



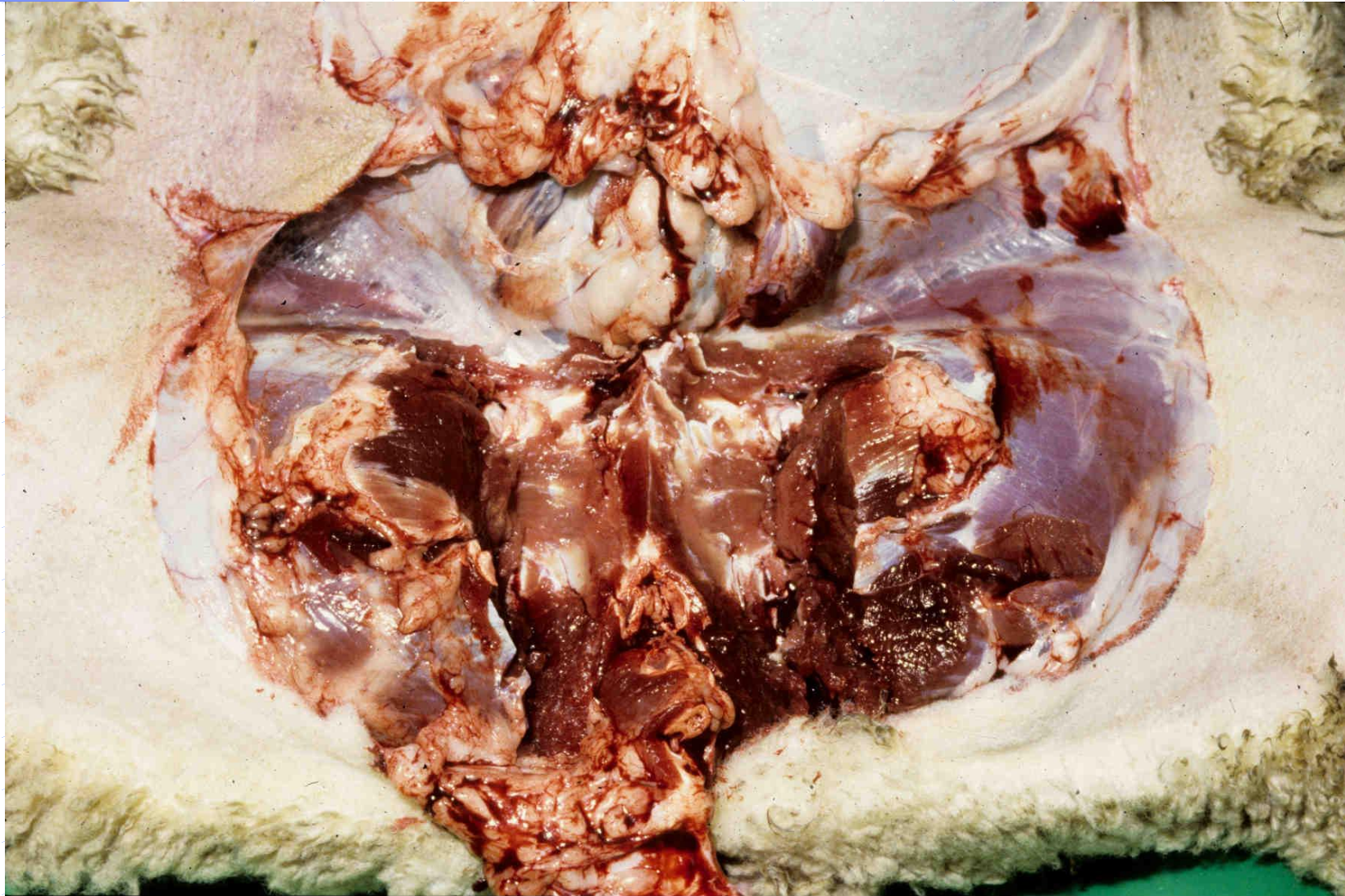
PM: Remove scrotum and contents



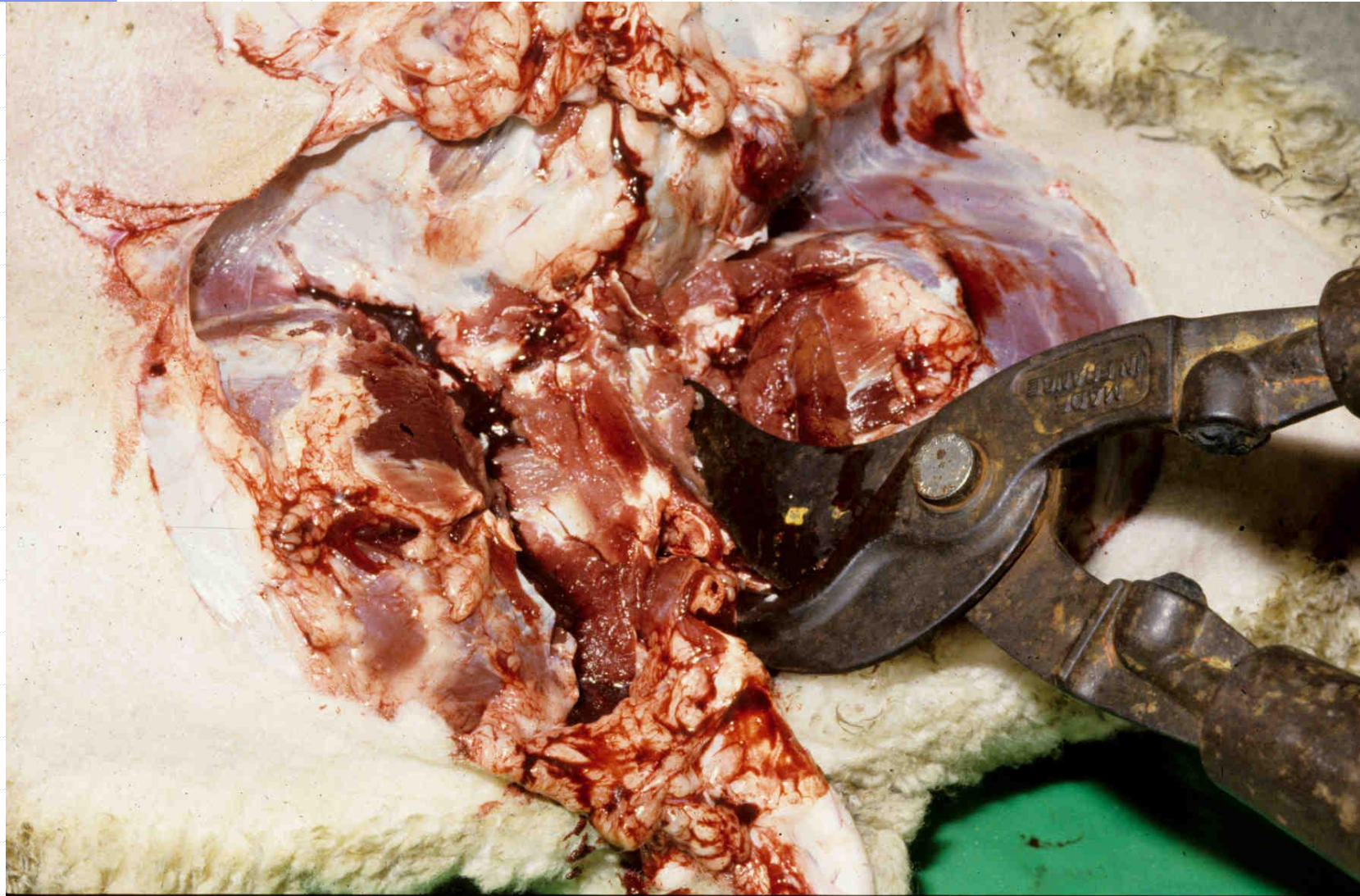
PM: Remove penis and prepuce



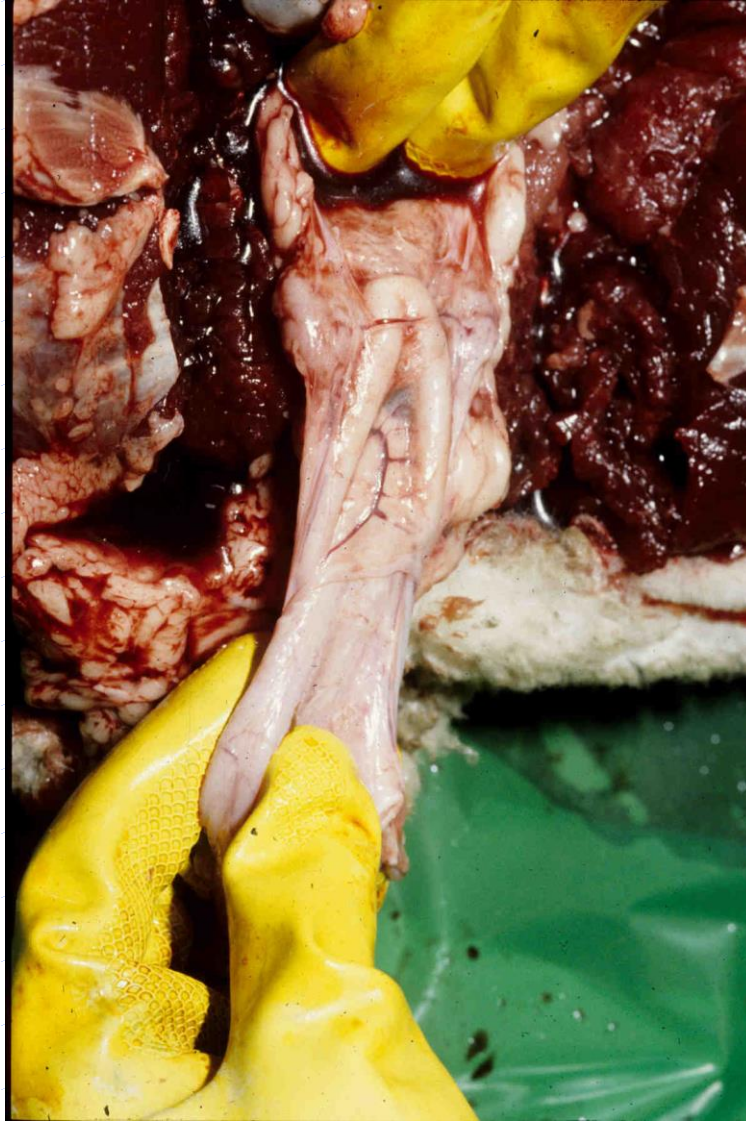
PM: Expose pelvis



PM: Cut window in pelvis



PM: Remove accessory genital glands




Sampling: Suitable fixatives

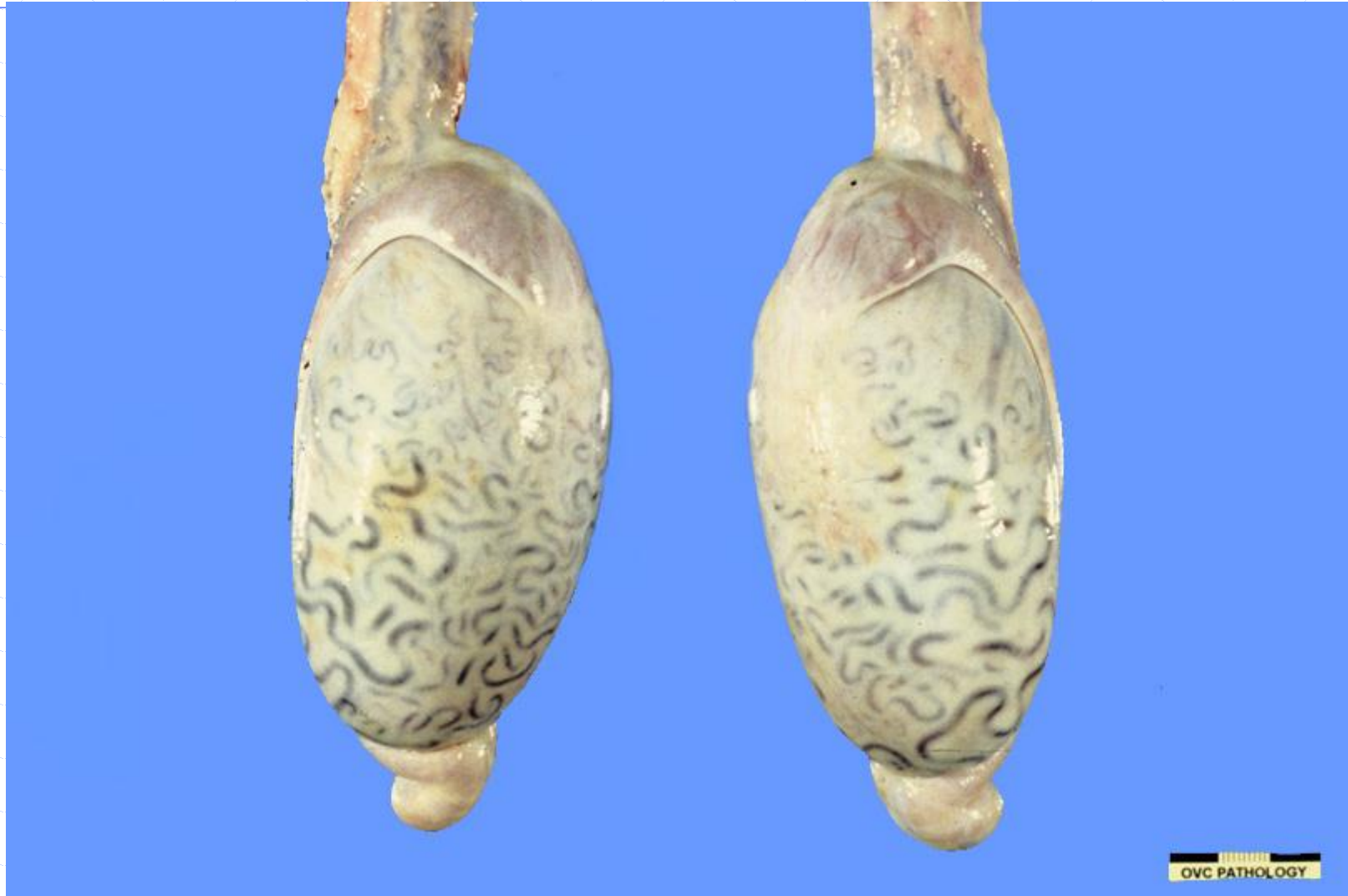- ◆ Formalin
(buffered neutral)
- ◆ Bouins fluid
 - Formalin
 - Picric acid
 - Acetic acid



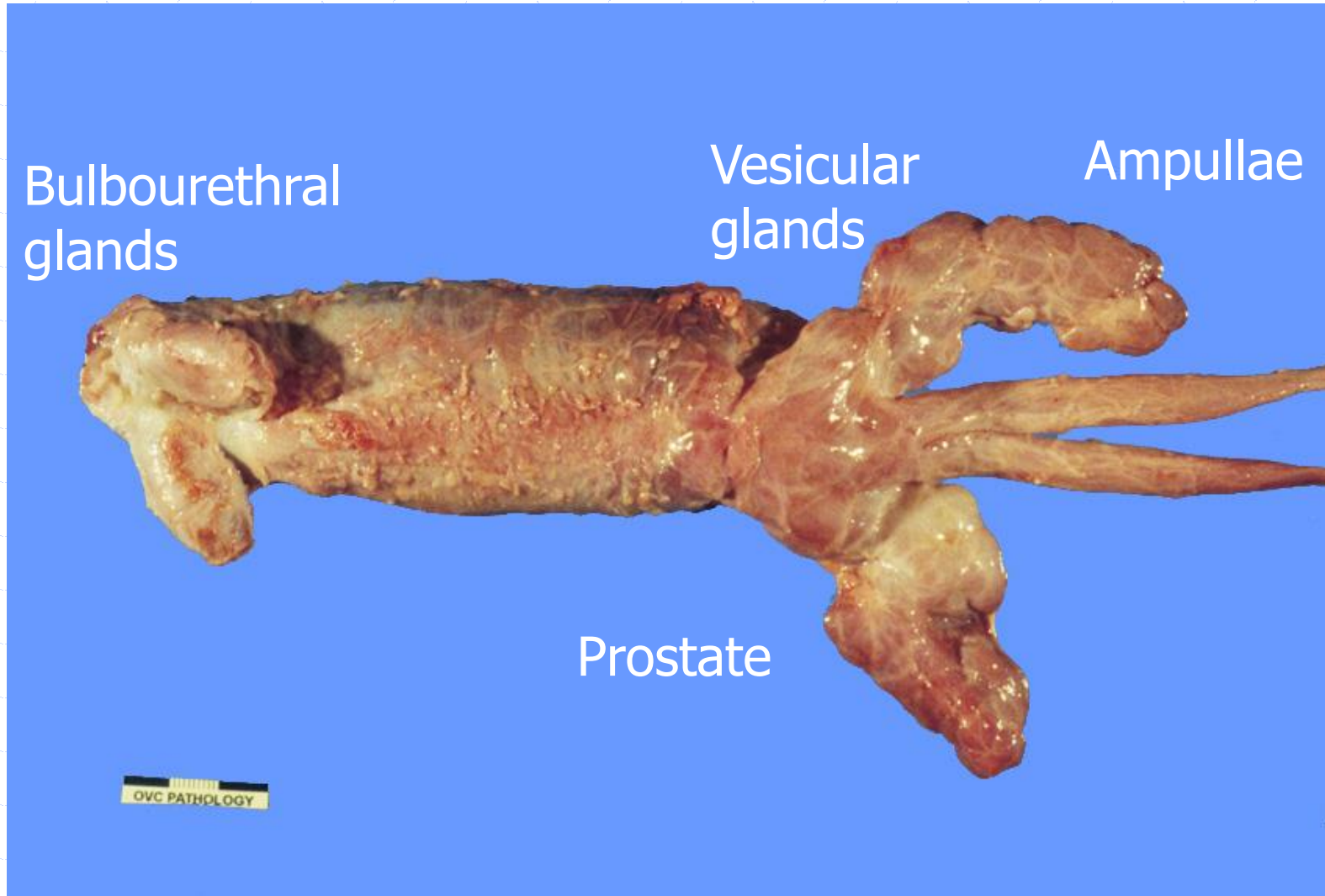
Sampling: Fixation of testes



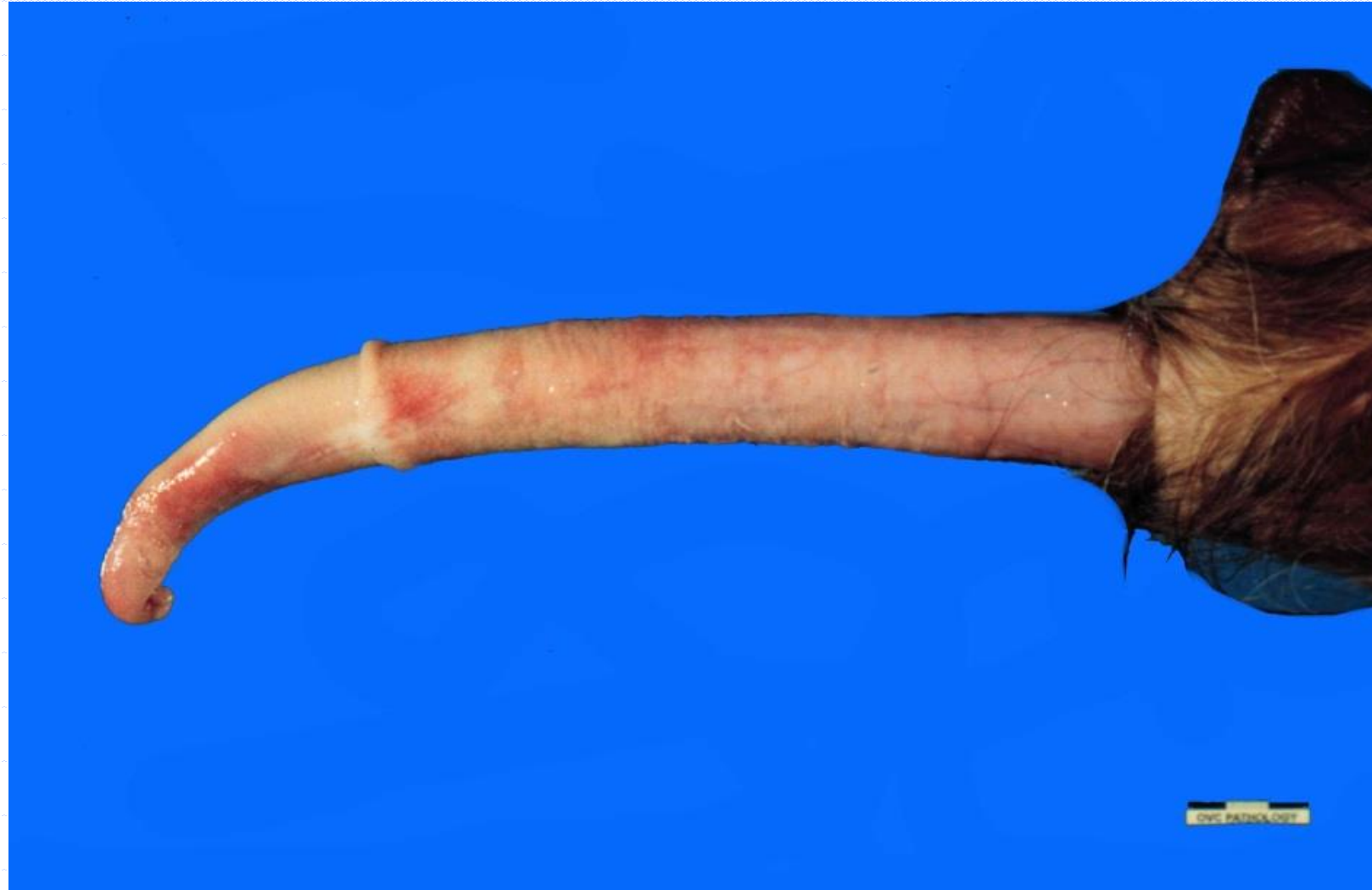Anatomy: Normal bull; scrotal contents



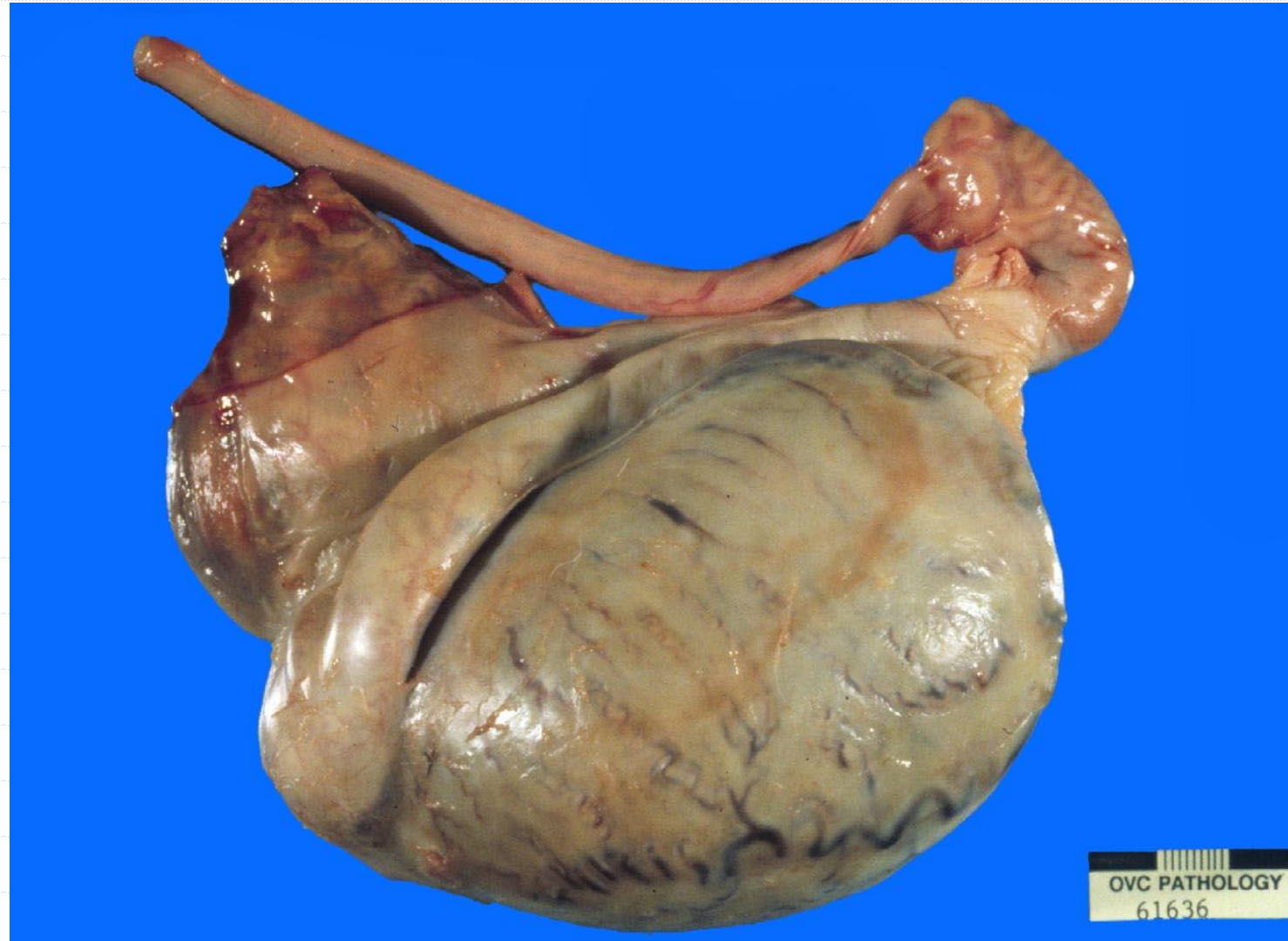Anatomy: Normal bull; accessory genital glands



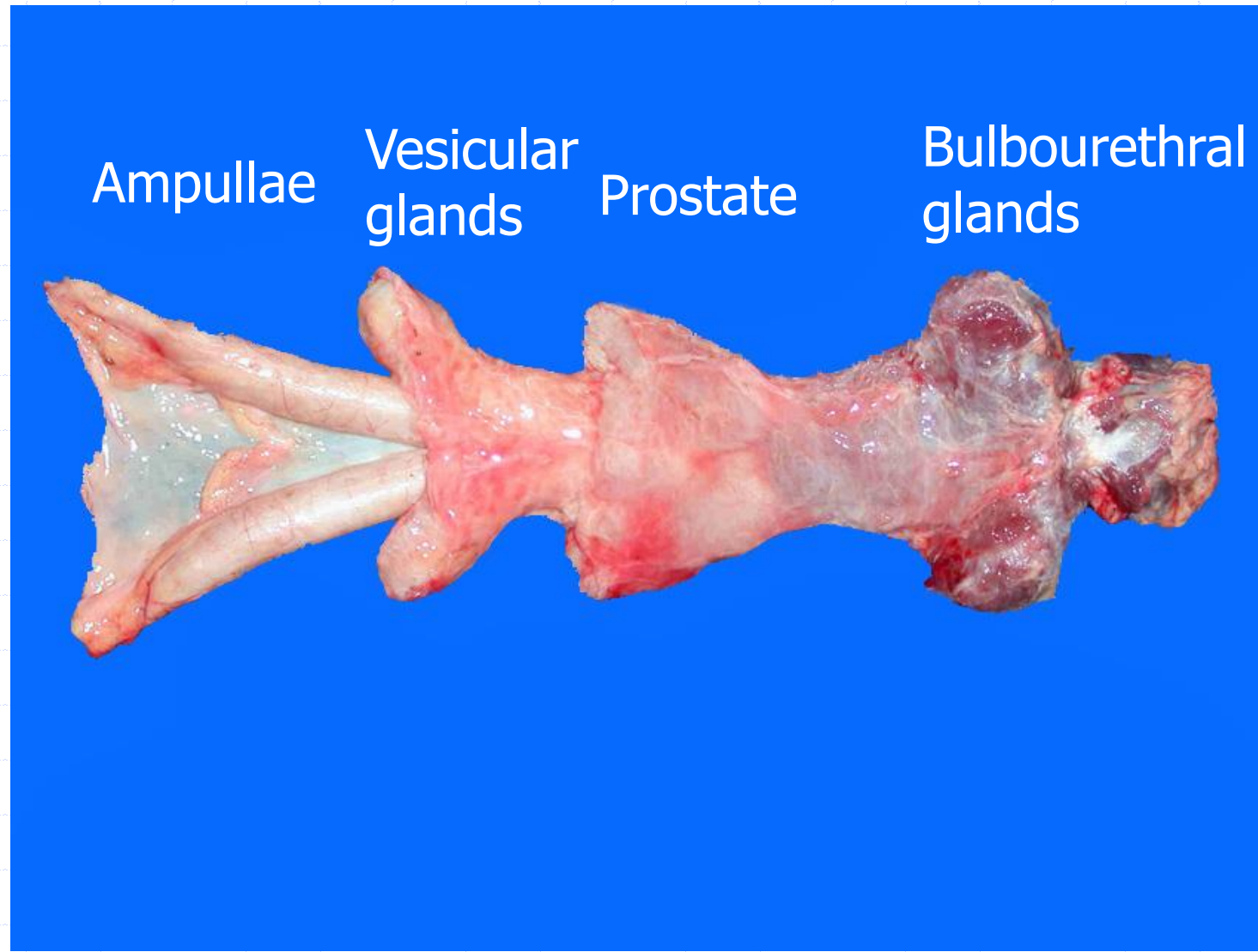
Anatomy: Normal bull; penis prepuce



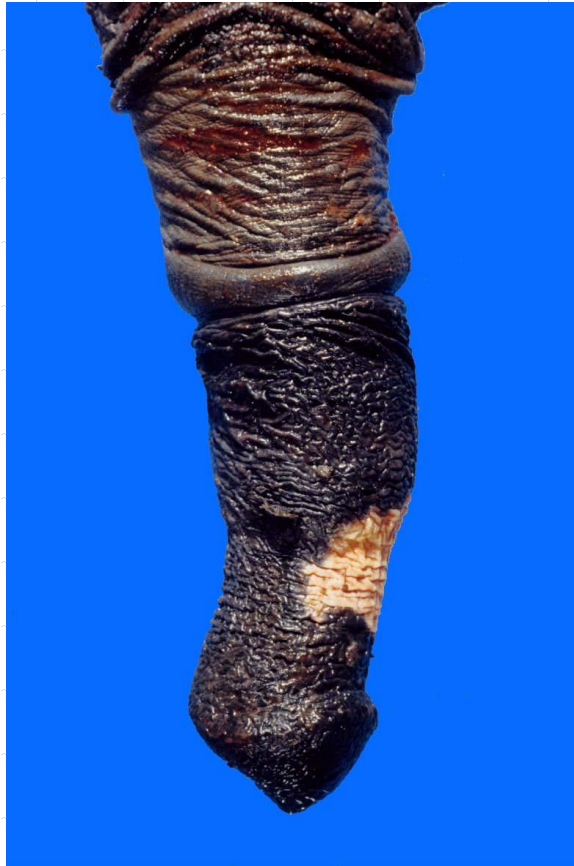Anatomy: Normal stallion; scrotal contents



Anatomy: Normal stallion; accessory genital glands

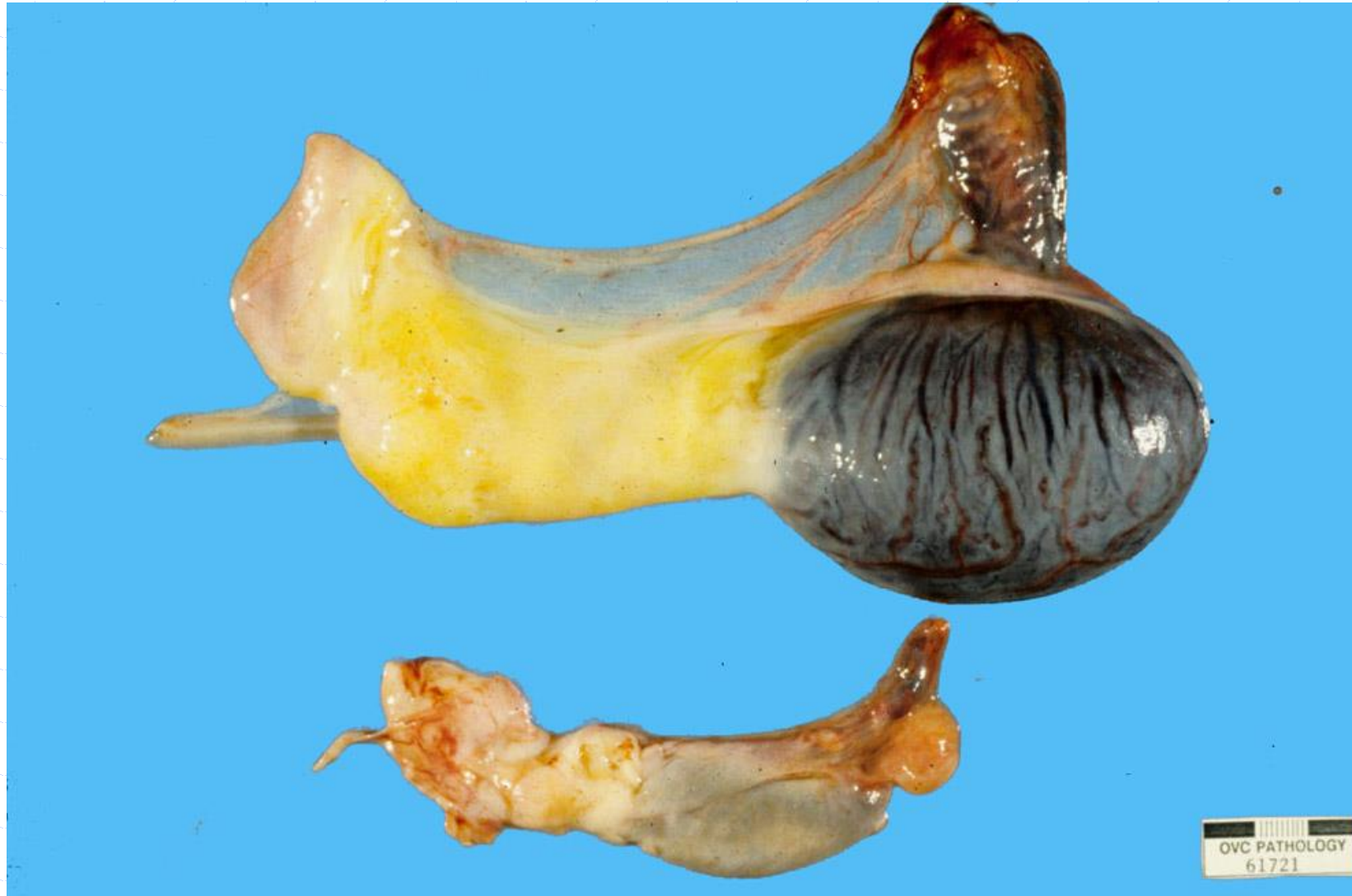

Anatomy: Normal stallion; penis prepuce

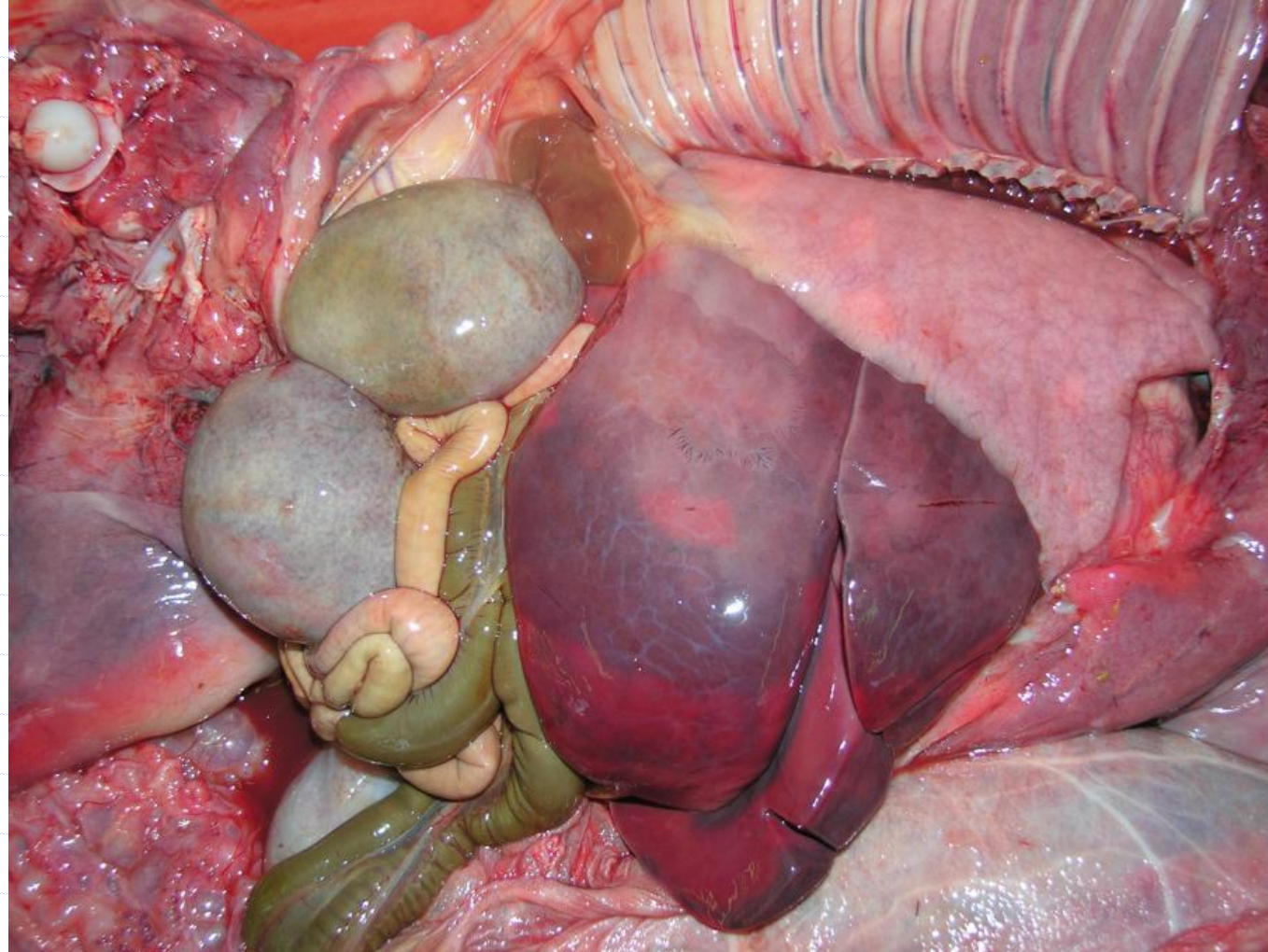


◆ Smegma

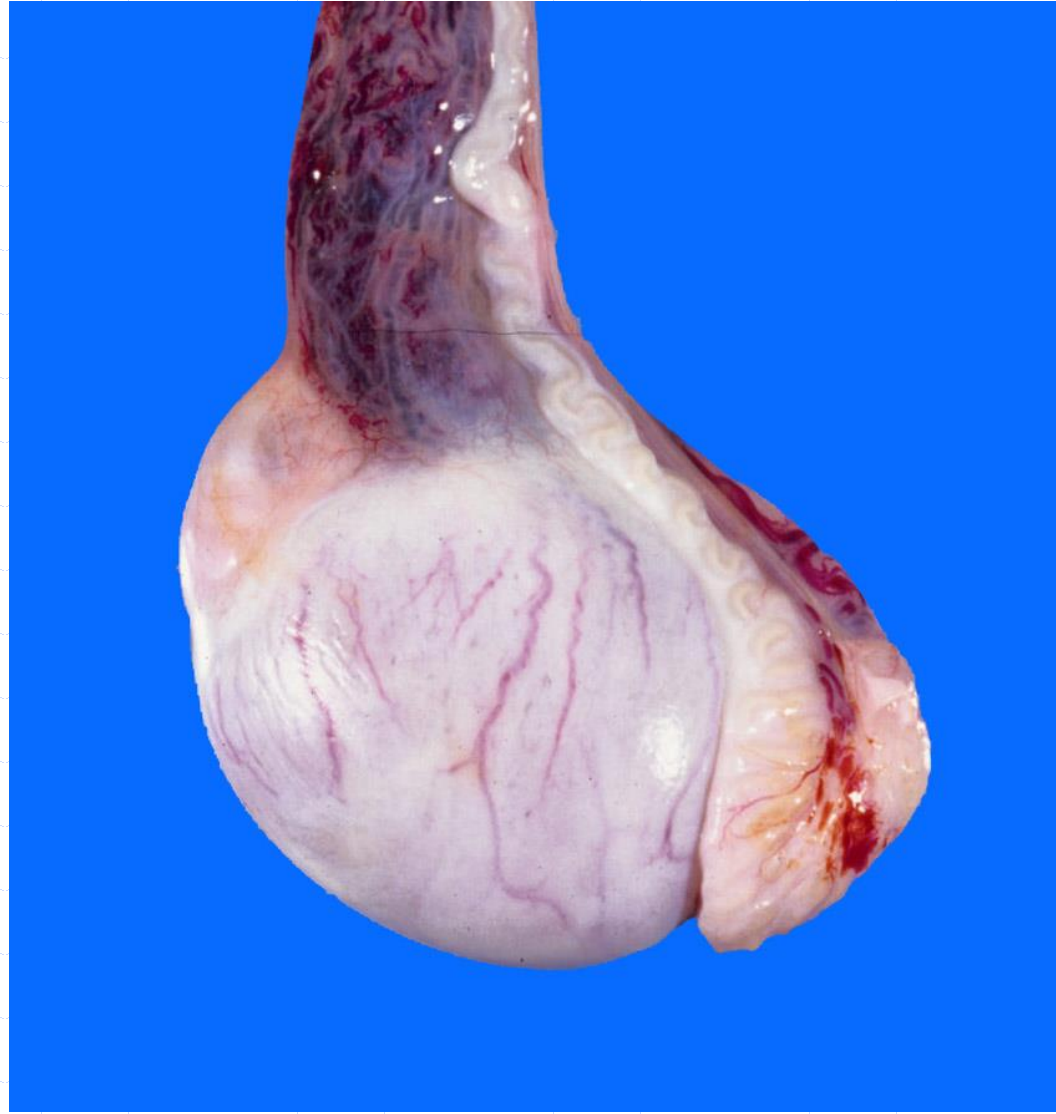Anatomy: Normal horse; fetal gonadal hypertrophy



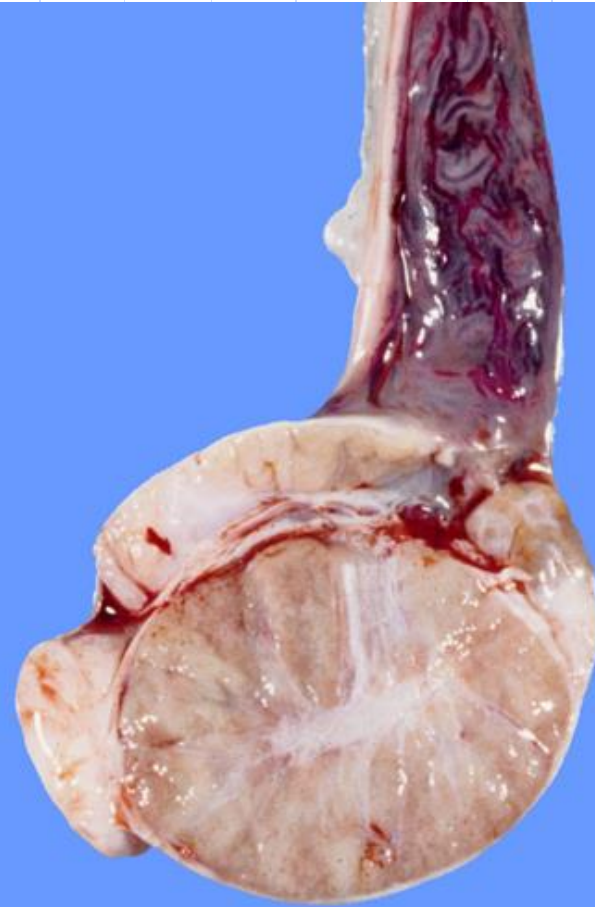
Anatomy: Normal horse; gonadal hypertrophy



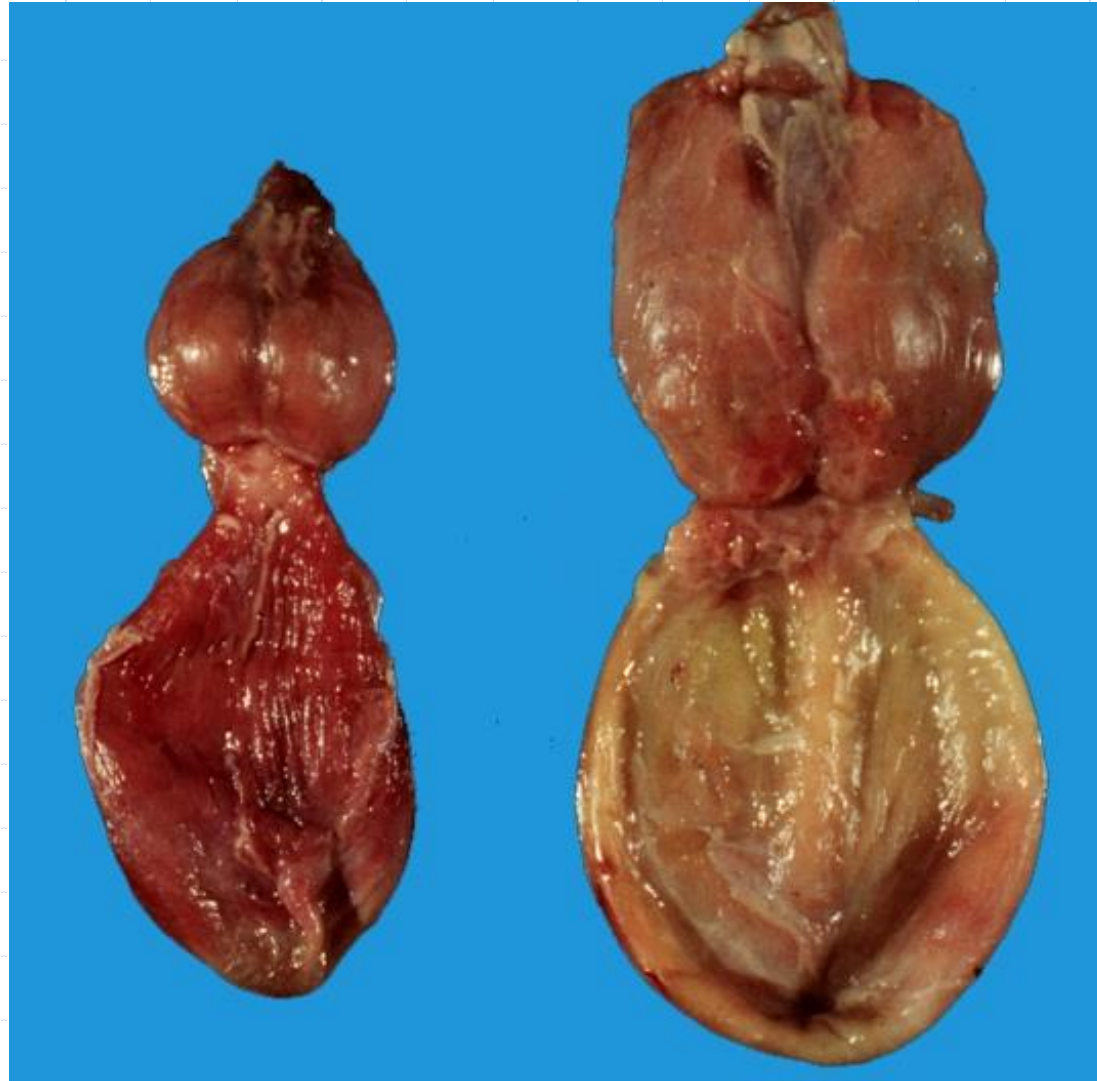Anatomy: Normal dog; scrotal contents



Anatomy: Normal dog; scrotal contents



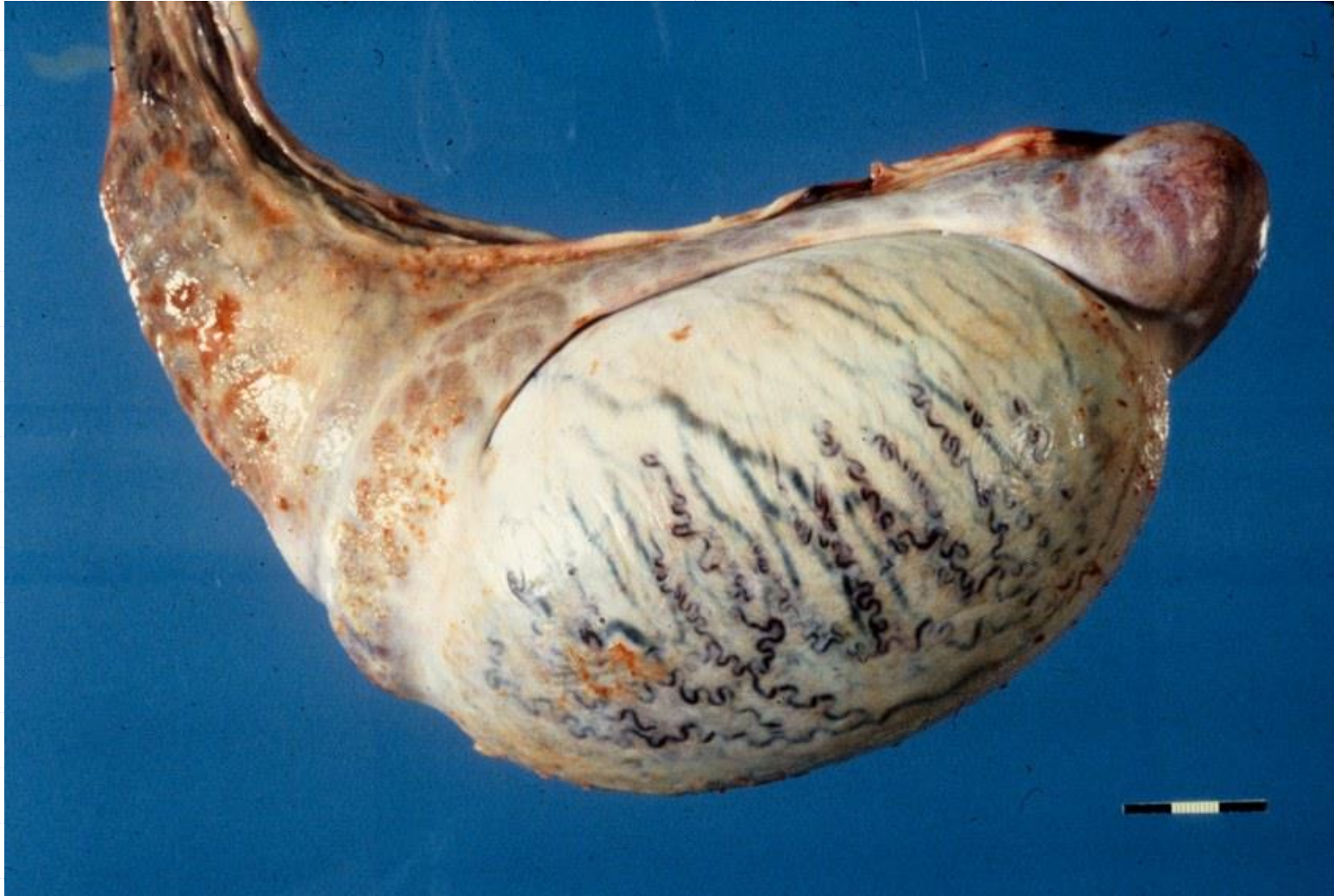Anatomy: Normal dog; accessory genital glands



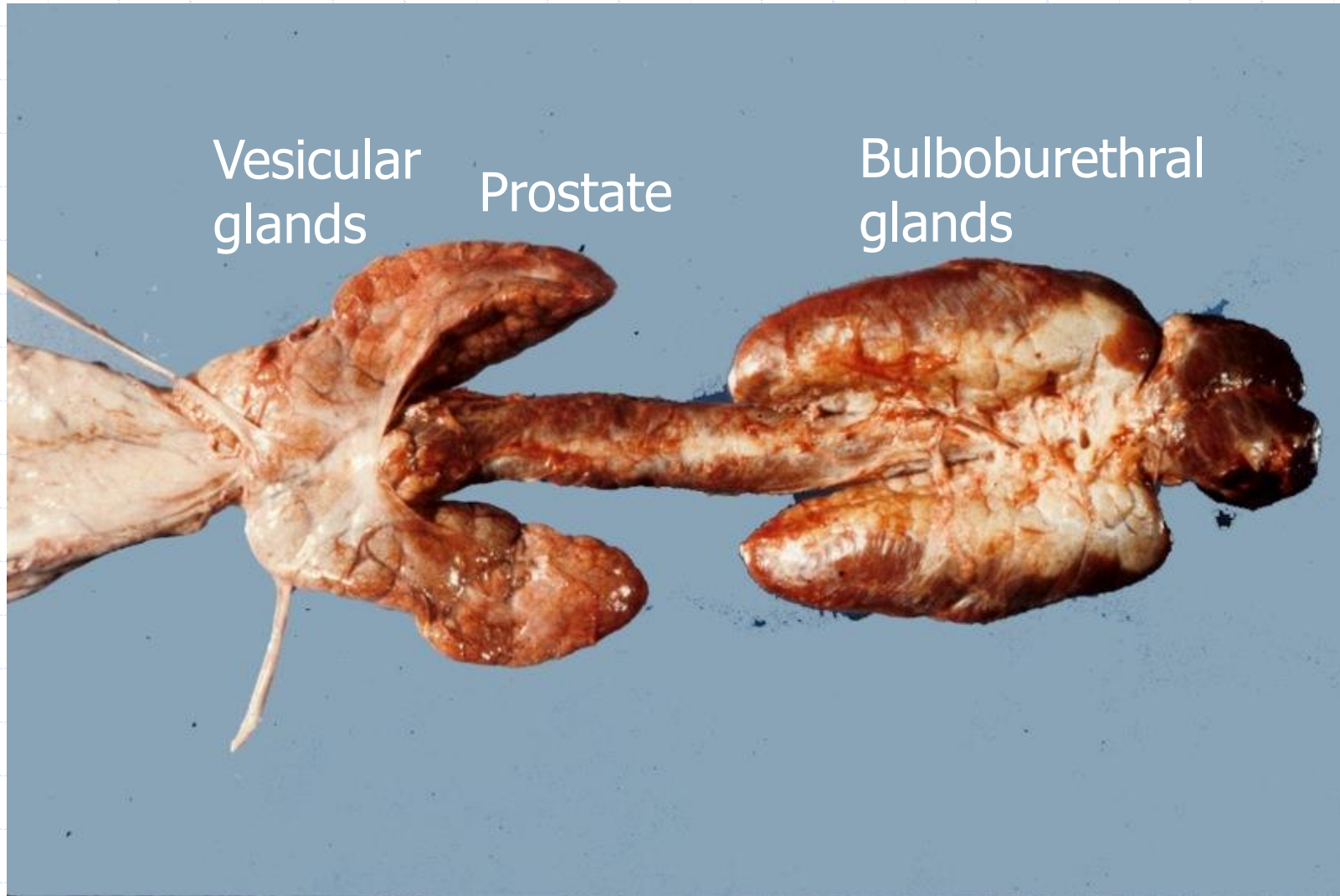
Anatomy: Normal dog; penis prepuce.



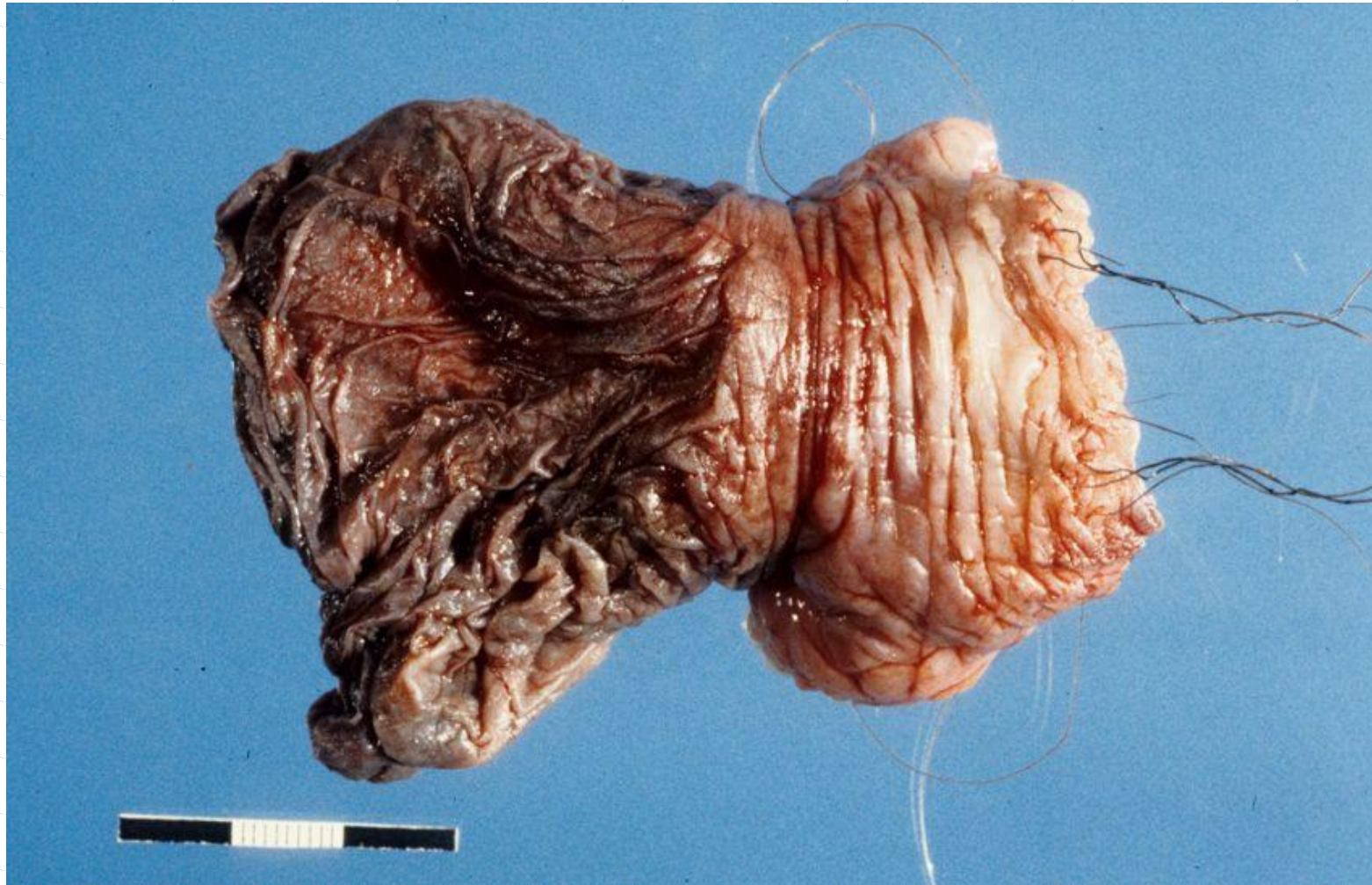Anatomy: Normal pig; scrotal contents



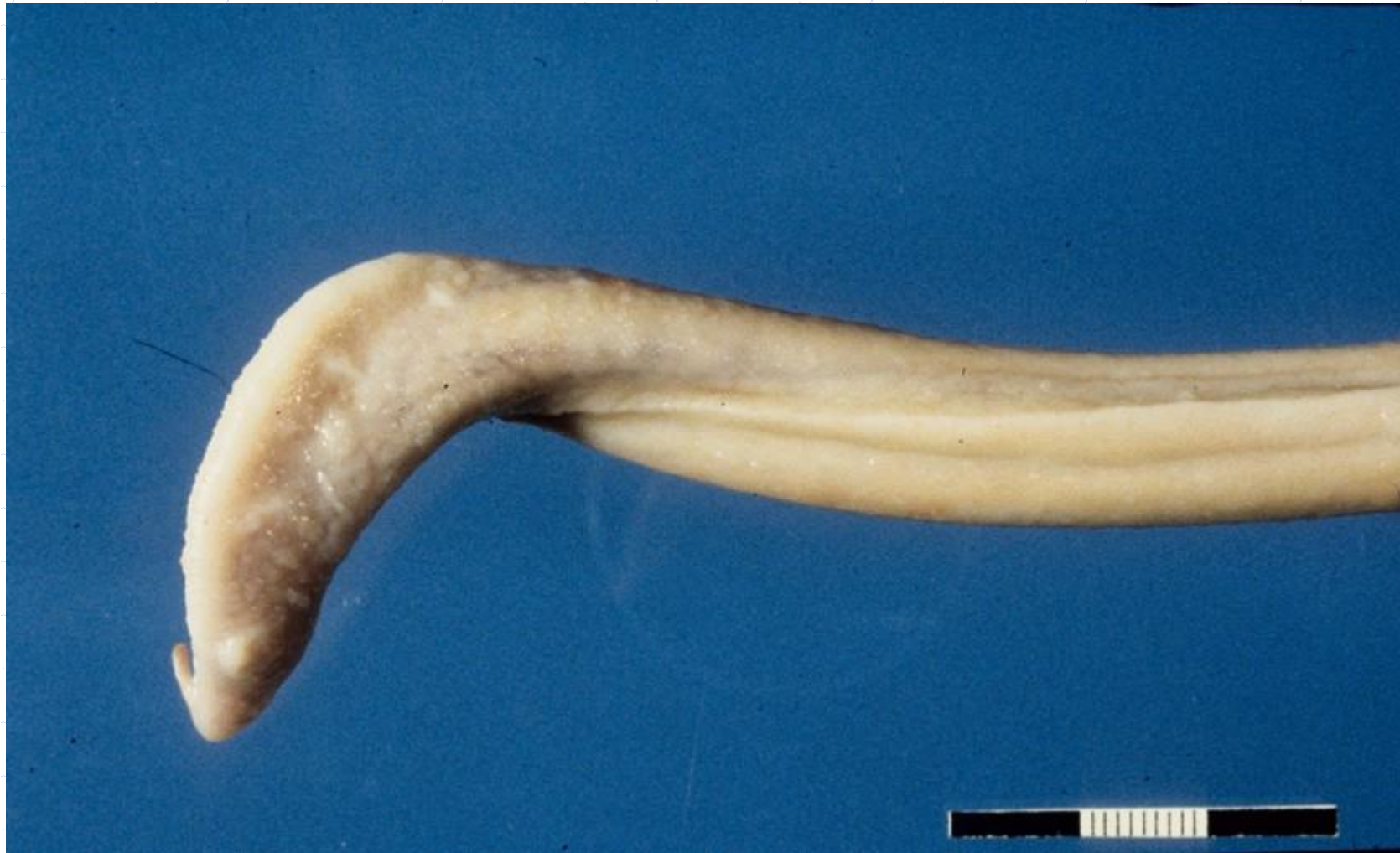Anatomy: Normal pig; accessory genital glands



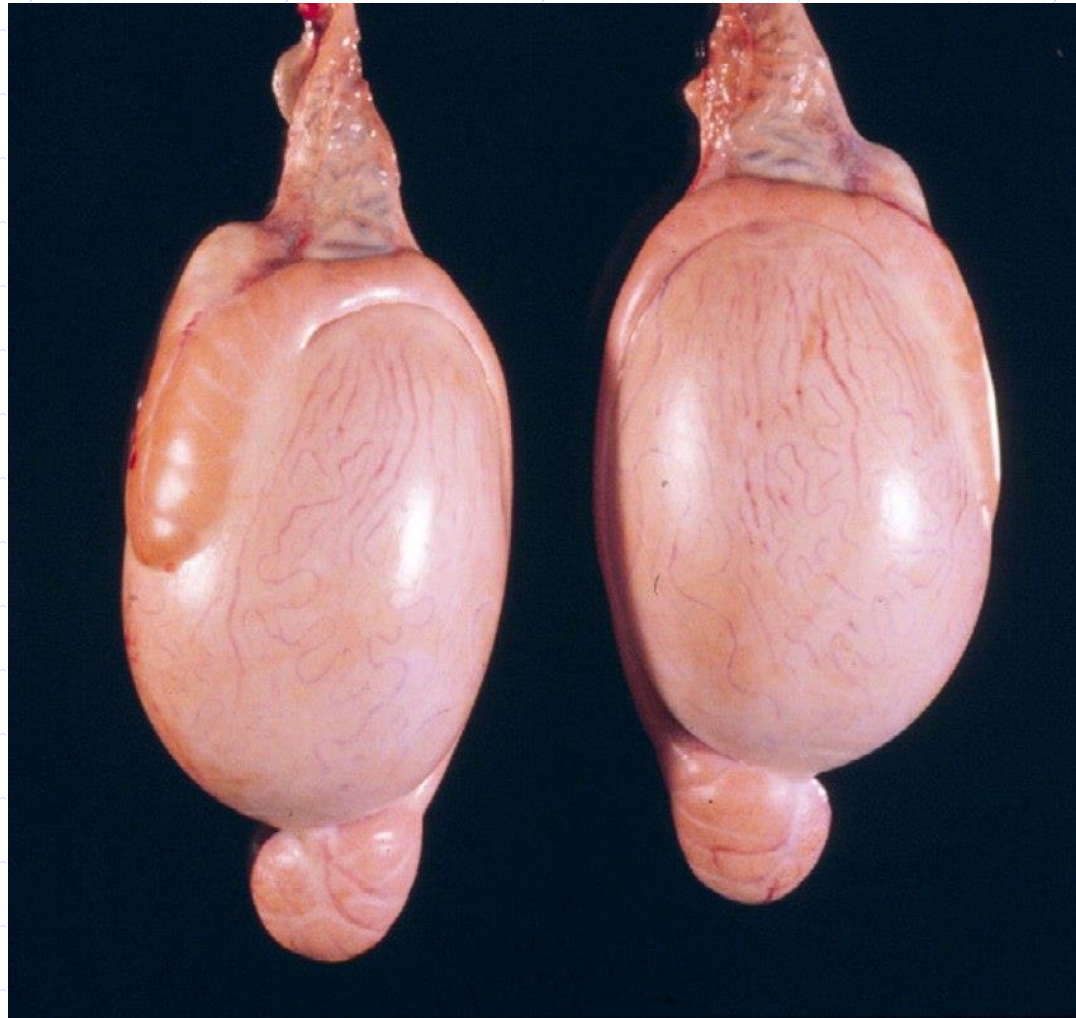Anatomy: Normal pig; Penis Prepuce - preputial diverticulum



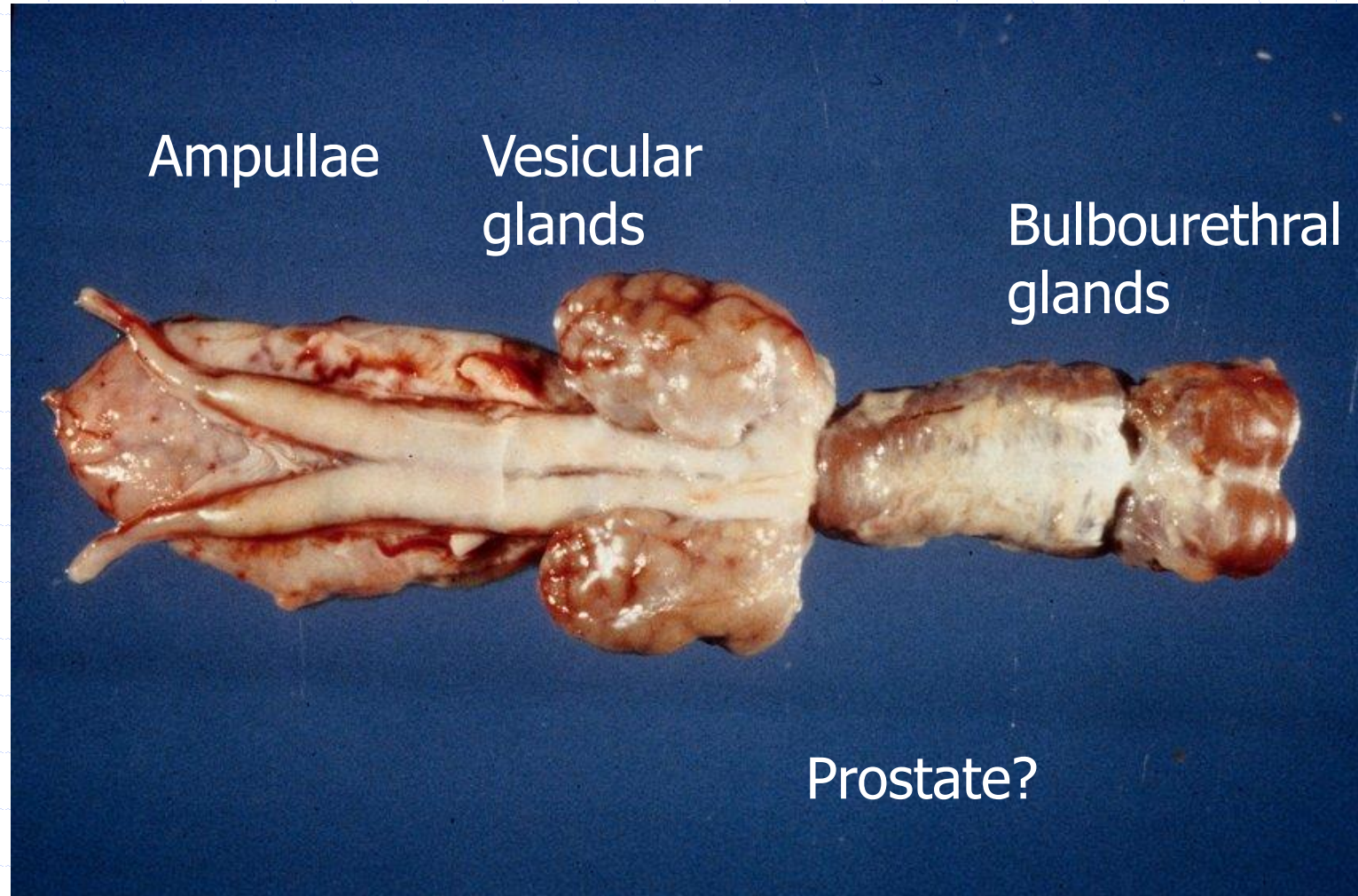
Anatomy: Normal pig; penis



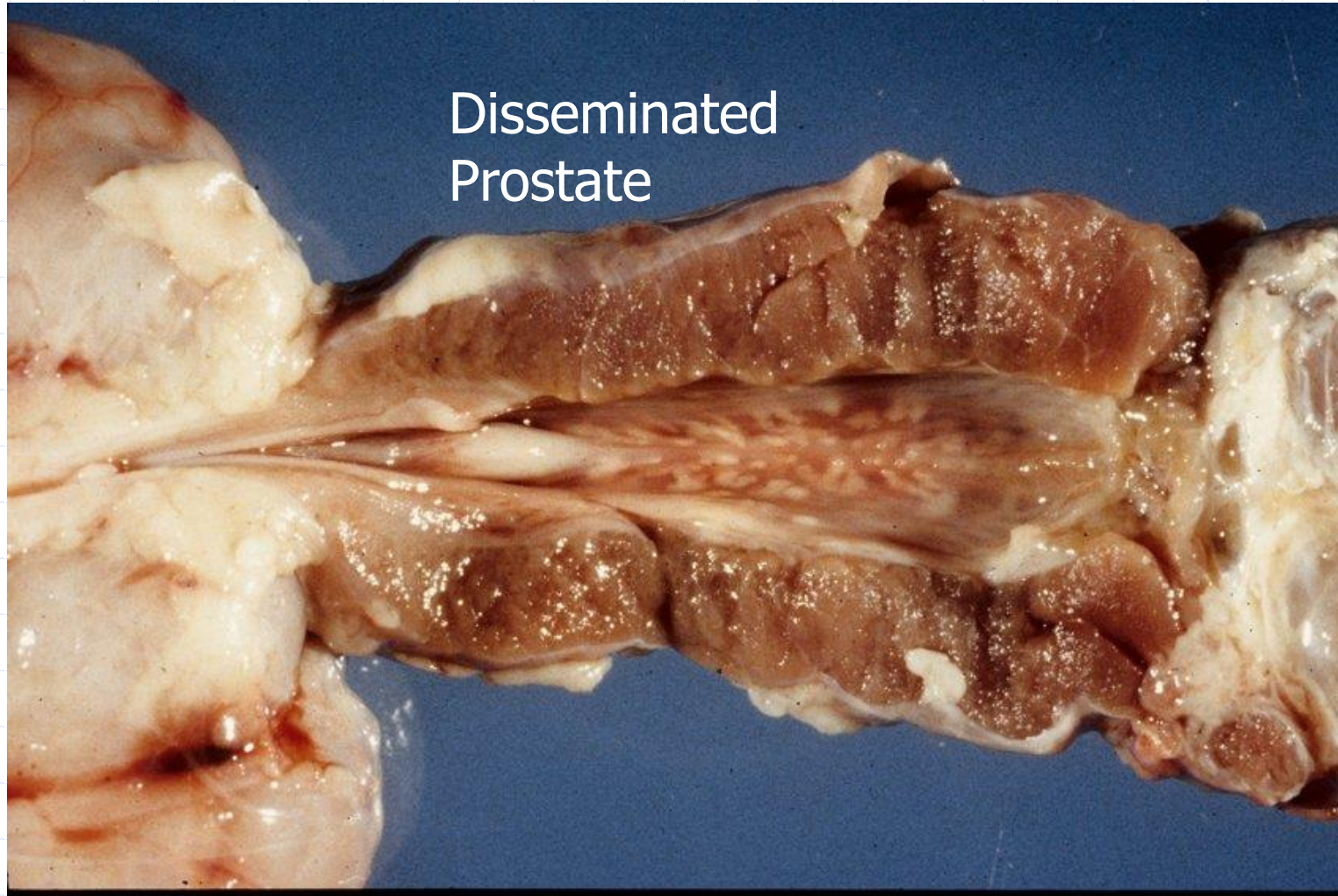
Anatomy: Normal small ruminant; scrotal contents



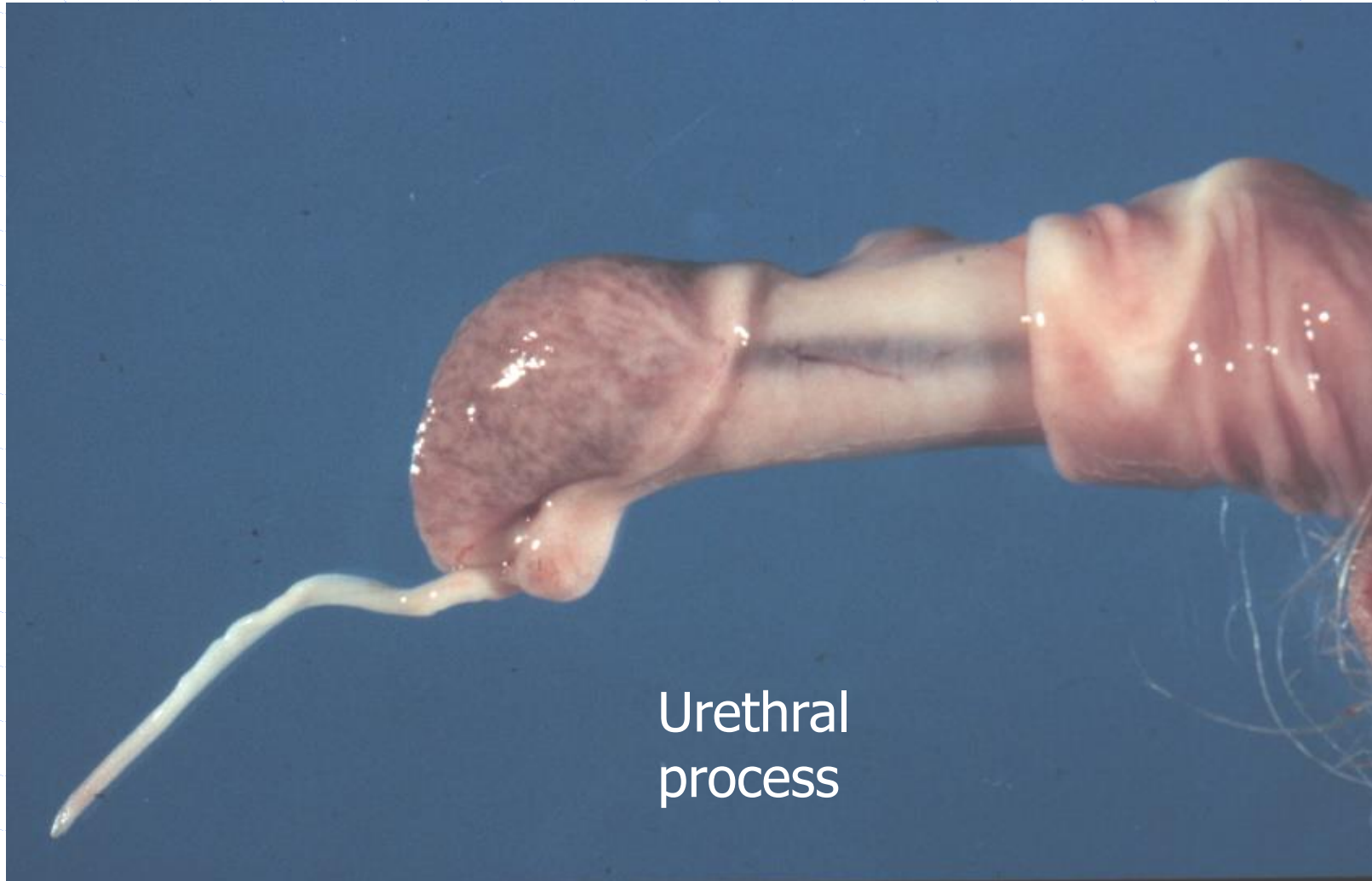
Anatomy: Normal small ruminant; accessory genital gland.



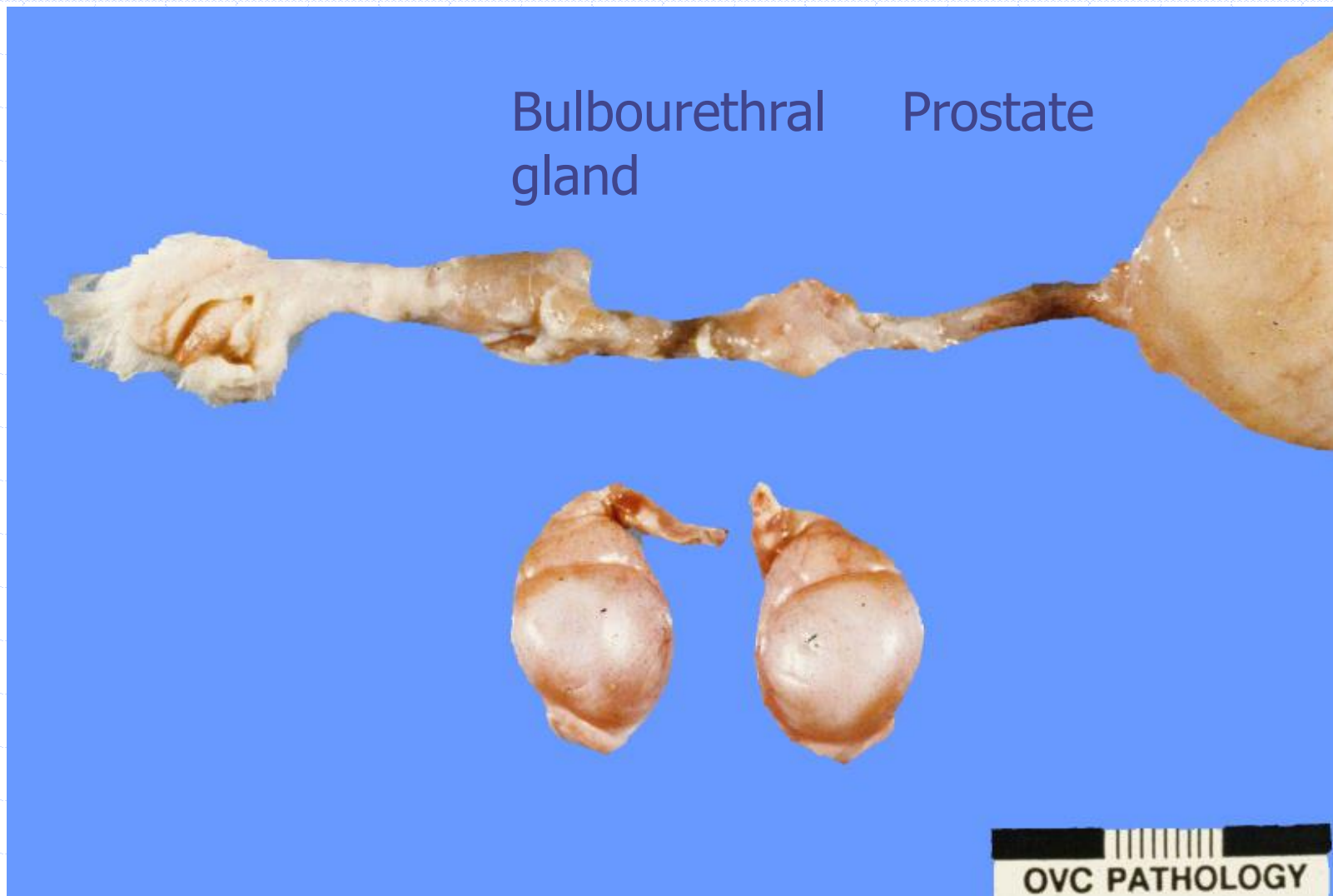
Anatomy: AGG; Normal small ruminant



Anatomy: Normal small ruminant



Anatomy: Normal tom cat



Normal Kangaroo

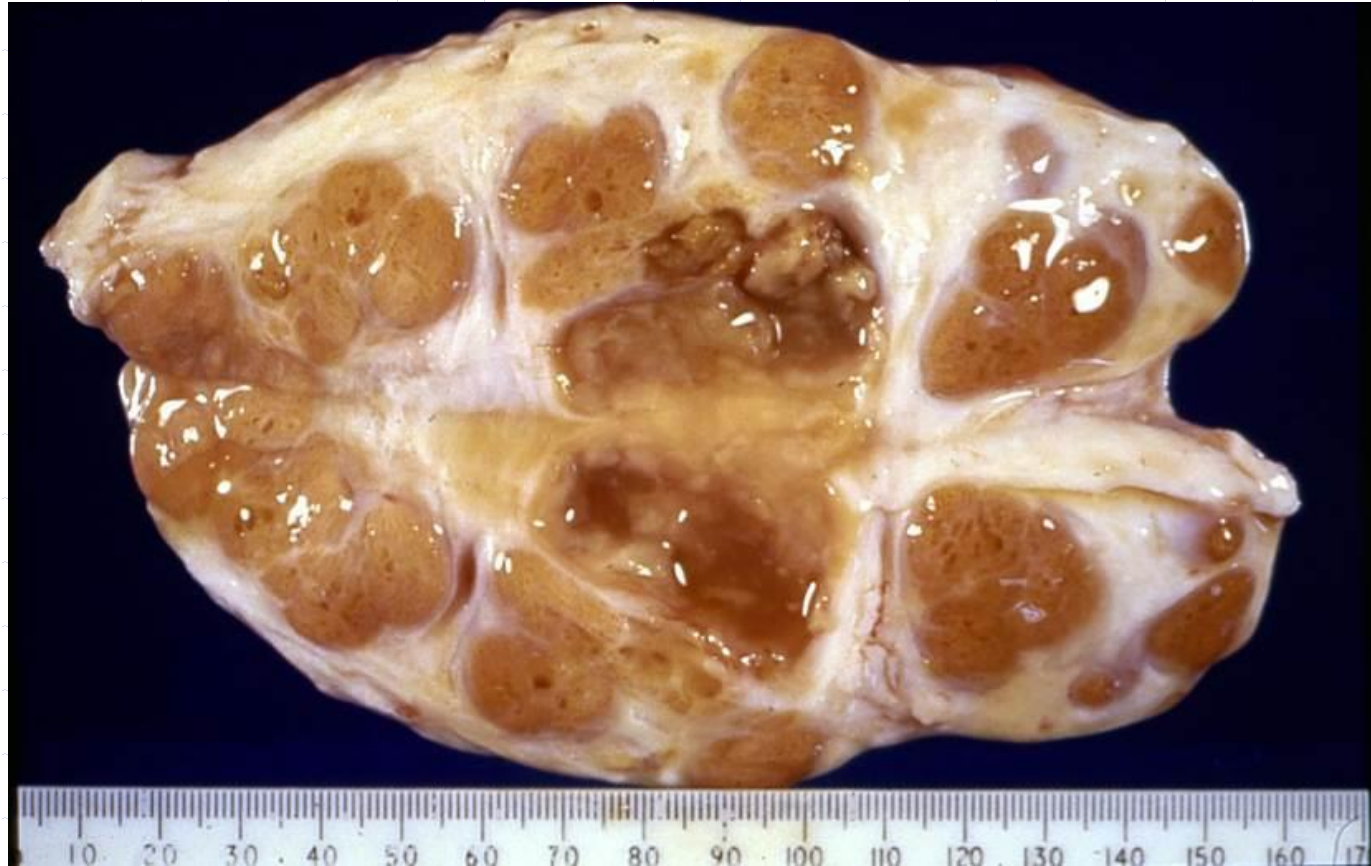◆ Prepenile scrotum



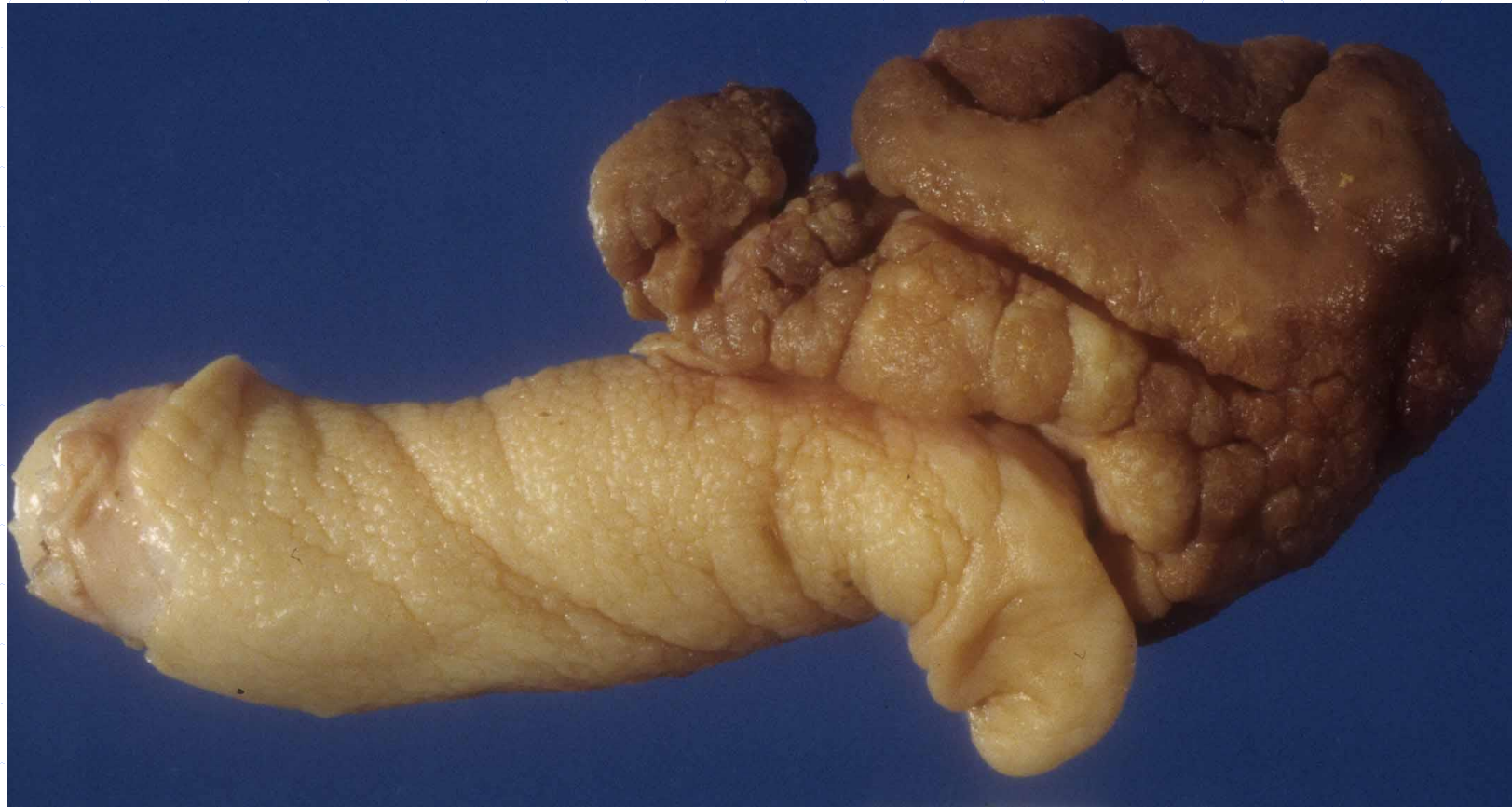Case examples.

- ◆ Provided with species
- ◆ You should be able to provide a:
 - Diagnosis
 - Pathogenesis
 - ◆ Cause
 - ◆ Mechanisms
 - ◆ Lesion

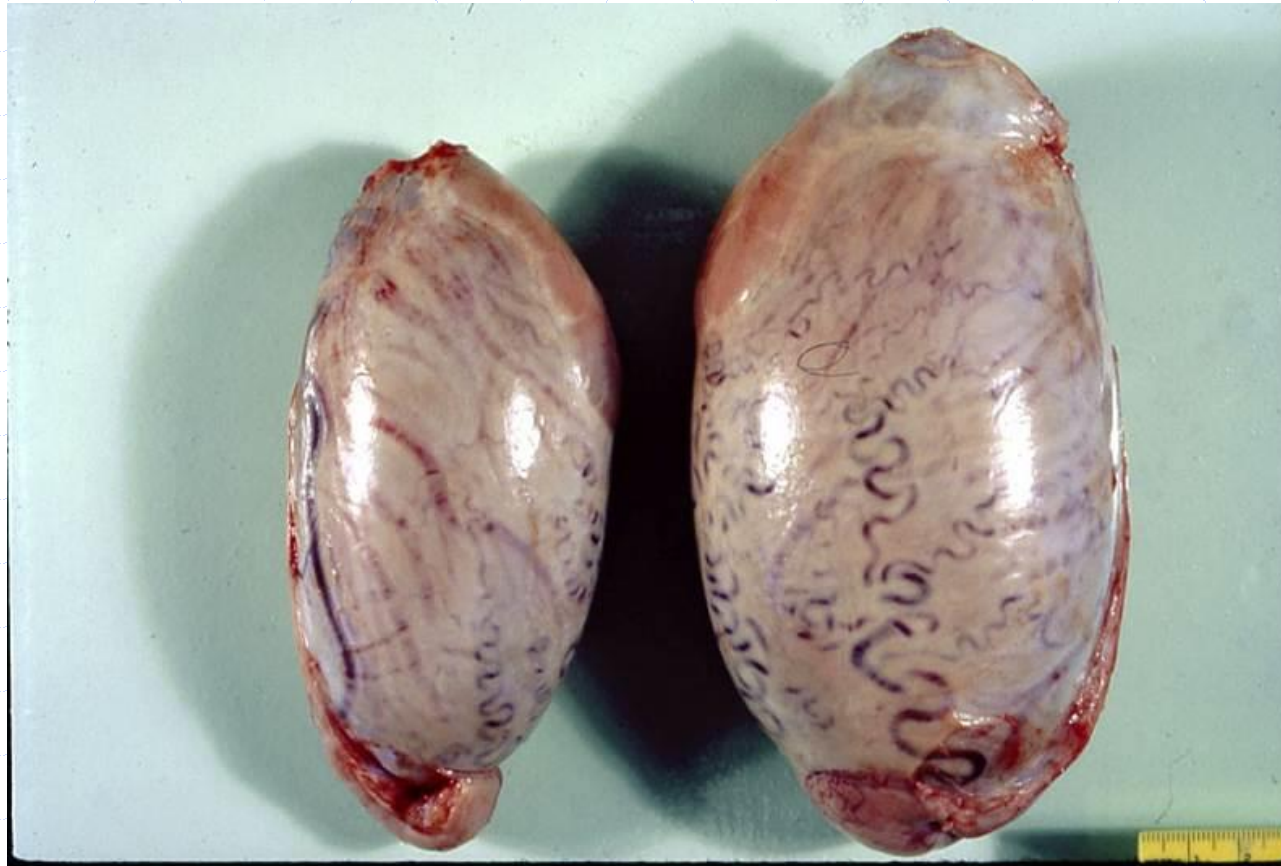Tissue from a accessory genital gland of a Bull with pyospermia.



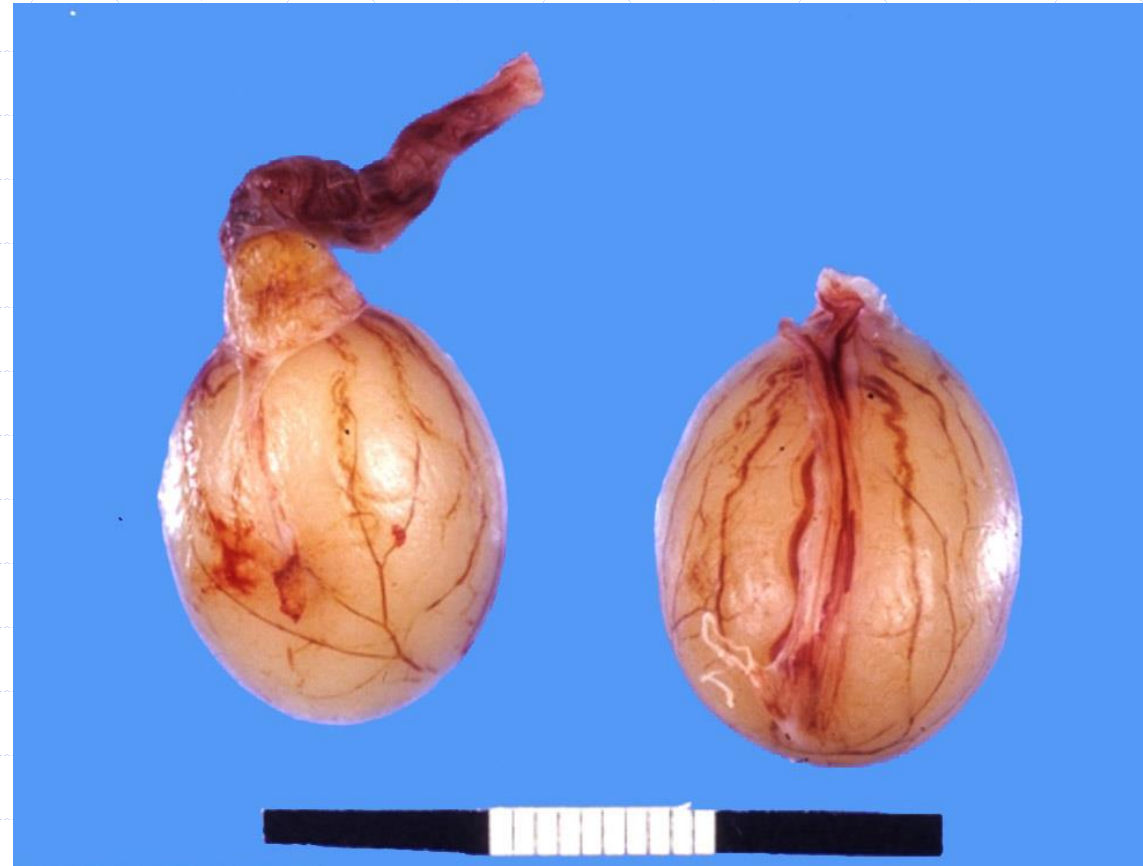Tissue from a bull with a penile mass.



Tissue from a bull with testicular asymmetry.



Tissue from an infertile dog



Tissue from a dog with scrotal enlargement

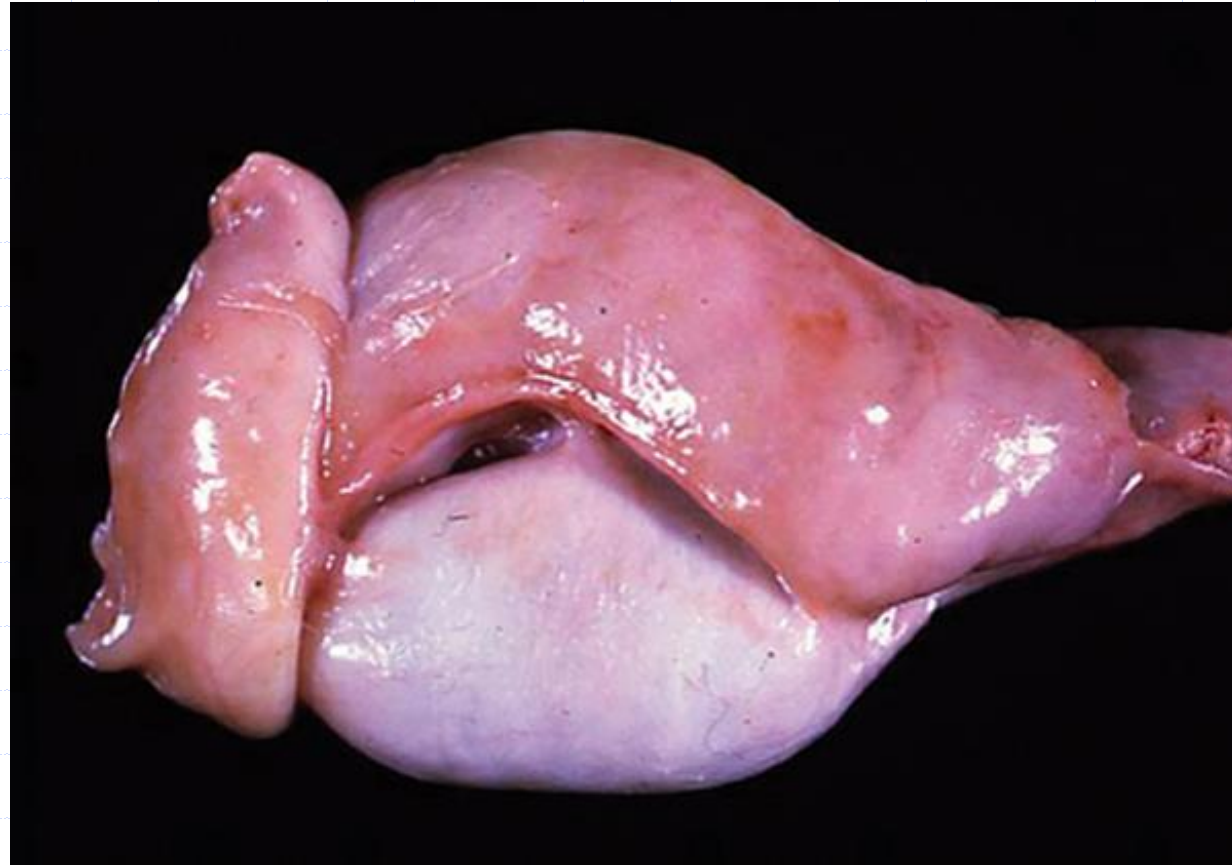
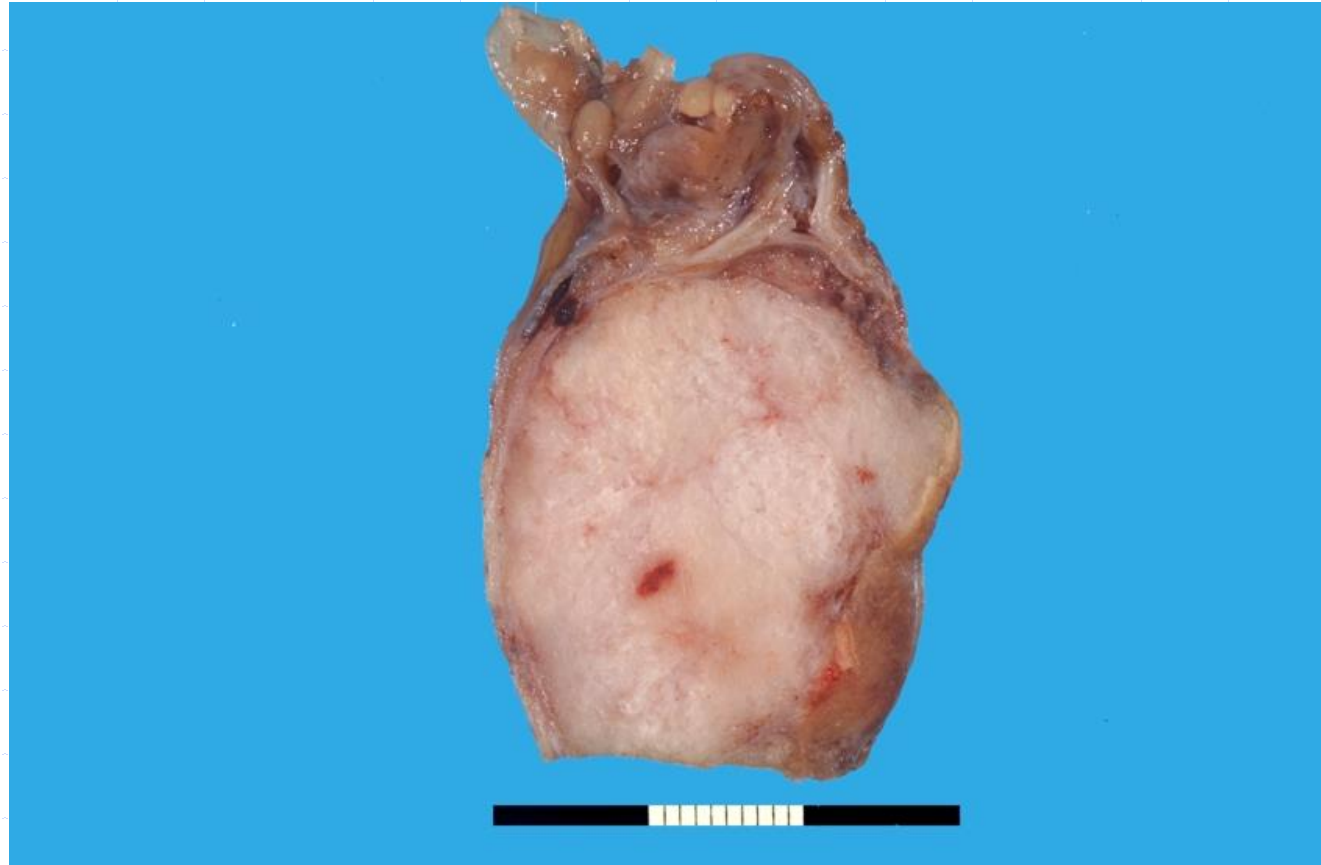
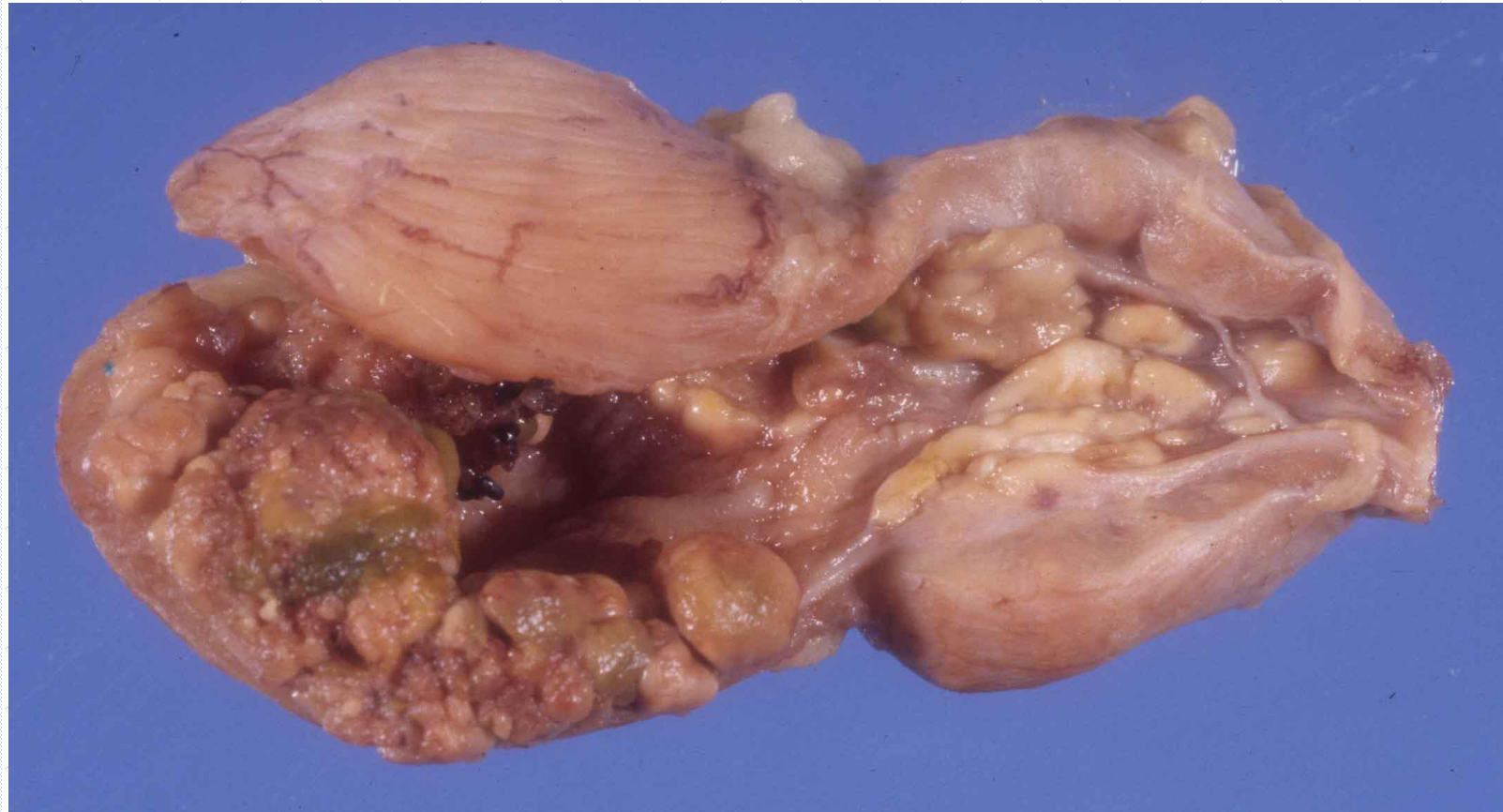
Photo complements of Pathological Basis of Veterinary Disease

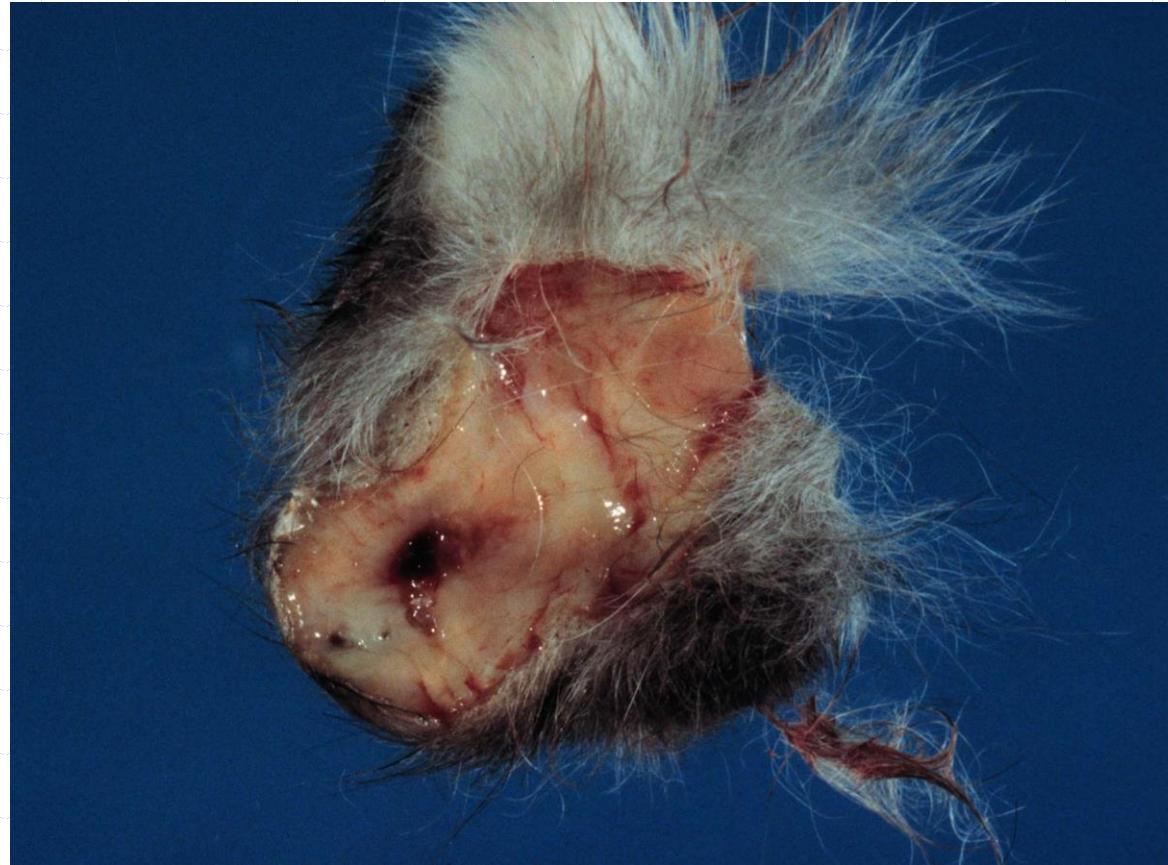Tissue from a dog with a large testis



Tissue from a dog with a large prostate



Tissue from a cat with scrotal swelling



Tissue from a stallion with scrotal swelling

